

## LONG-TERM TREATMENT OF PRIMARY PULMONARY HYPERTENSION WITH AEROSOLIZED ILOPROST, A PROSTACYCLIN ANALOGUE

MARIUS M. HOEPER, M.D., MICHAEL SCHWARZE, STEFAN EHLENDING, ANGELIKA ADLER-SCHUERMEYER, R.N., EDDA SPIEKERKOEETTER, M.D., JOST NIEDERMEYER, M.D., MICHAEL HAMM, M.D., AND HELMUT FABEL, M.D.

### ABSTRACT

**Background** Continuous intravenous infusion of epoprostenol (prostacyclin) is an effective treatment for primary pulmonary hypertension. This approach requires the insertion of a permanent central venous catheter, with the associated risk of serious complications. Recently, aerosolized iloprost, a stable prostacyclin analogue, has been introduced as an alternative therapy for severe pulmonary hypertension.

**Methods** We evaluated the effects of aerosolized iloprost on exercise capacity and hemodynamic variables over a one-year period in patients with primary pulmonary hypertension.

**Results** Twenty-four patients with primary pulmonary hypertension received aerosolized iloprost at a daily dose of 100 or 150  $\mu\text{g}$  for at least one year. The mean ( $\pm$ SD) distance covered in the six-minute walk test increased from  $278\pm 96$  m at base line to  $363\pm 135$  m after 12 months ( $P<0.001$ ). During the same period, the mean pulmonary arterial pressure before the inhalation of iloprost declined from  $59\pm 10$  mm Hg to  $52\pm 15$  mm Hg ( $P=0.006$ ), cardiac output increased from  $3.8\pm 1.4$  liters per minute to  $4.4\pm 1.3$  liters per minute ( $P=0.02$ ), and pulmonary vascular resistance declined from  $1205\pm 467$  dyn $\cdot$ sec $\cdot$ cm $^{-5}$  to  $925\pm 469$  dyn $\cdot$ sec $\cdot$ cm $^{-5}$  ( $P<0.001$ ). The treatment was generally well tolerated, except for mild coughing, minor headache, and jaw pain in some patients.

**Conclusions** Long-term treatment with aerosolized iloprost is safe and has sustained effects on exercise capacity and pulmonary hemodynamics in patients with primary pulmonary hypertension. (N Engl J Med 2000;342:1866-70.)

©2000, Massachusetts Medical Society.

SEVERAL studies have shown that continuous intravenous epoprostenol (prostacyclin) improves exercise tolerance, hemodynamic variables, and survival in patients with primary pulmonary hypertension.<sup>1-7</sup> This treatment, however, has two substantial drawbacks. One is the occurrence of tolerance, which in some patients necessitates continuous dose escalation and therefore contributes to the high cost of treatment. The other, clinically more pertinent problem is the risk of serious infection, catheter thrombosis, and pump failure associated with the permanent central venous catheter and delivery system. Although the risk of these complications has been reported to be low,<sup>4,7</sup> they are potentially life-threatening.

These shortcomings might be overcome by the administration of aerosolized iloprost,<sup>8</sup> a stable prostacyclin analogue, as suggested by Olschewski et al.<sup>9,10</sup> When administered by inhalation, iloprost is a potent pulmonary vasodilator with more pronounced short-term hemodynamic effects than inhaled nitric oxide in patients with primary pulmonary hypertension.<sup>11</sup> Preliminary studies have shown that intermittent inhalation of iloprost has beneficial short-term effects in patients with primary and secondary pulmonary hypertension.<sup>11,12</sup> However, only limited data are available on the long-term efficacy of treatment with aerosolized iloprost in patients with primary pulmonary hypertension.<sup>9</sup>

We studied the effects of administering aerosolized iloprost over a one-year period to patients with primary pulmonary hypertension.

### METHODS

#### Patients

We studied the clinical course of consecutive patients who were referred to our center for the treatment of pulmonary hypertension between March 1997 and June 1998 and who had primary pulmonary hypertension according to the diagnostic criteria of the National Institutes of Health Registry on Primary Pulmonary Hypertension.<sup>13</sup> Patients with secondary pulmonary hypertension were excluded, as were patients with severe right heart failure who were receiving catecholamines at the time of their initial presentation and those lost to follow-up.

#### Treatment and Follow-up

In Germany, neither intravenous epoprostenol nor aerosolized iloprost has been licensed for the treatment of pulmonary hypertension. At our center, aerosolized iloprost is being offered, on a compassionate-use basis, as first-line therapy for the majority of patients with advanced primary pulmonary hypertension. This approach was approved by our institution's ethics committee; all patients in this study were informed about the investigational character of the treatment and gave written informed consent.

To be eligible for treatment with aerosolized iloprost, patients had to have pulmonary hypertension with severe limitation of exercise capacity (New York Heart Association functional class III or IV) that was refractory to conventional medical treatment, including the use of calcium-channel blockers. Exercise capacity was determined by the six-minute walk test after the patient had performed one or two walks to become familiar with the route.<sup>14</sup>

Hemodynamic variables were assessed by catheterization of the right side of the heart. Cardiac output was measured by the thermodilution technique.<sup>15</sup> After the base-line hemodynamic variables had been recorded, the short-term hemodynamic response to aer-

From the Department of Respiratory Medicine, Hannover Medical School, Hannover, Germany. Address reprint requests to Dr. Hoepfer at the Department of Respiratory Medicine, Hannover Medical School, 30623 Hannover, Germany, or at kmhoepfer@aol.com.

osolized iloprost was measured. For that purpose, 50 µg of iloprost (Ilomedin, Schering, Berlin, Germany) was diluted in 5 ml of isotonic saline, aerosolized in a jet nebulizer (Ilo-Neb, Nebu-Tec, Elsenfeld, Germany) and administered over a period of 10 to 15 minutes, which resulted in a cumulative dose of nebulized iloprost between 14 and 17 µg. Immediately after inhalation and every 15 minutes thereafter for up to 1 hour, the hemodynamic variables were measured in order to determine the maximal short-term effect of inhaled iloprost and the timing of the hemodynamic response.

All patients started treatment with a daily dose of 100 µg of aerosolized iloprost, divided into six or eight inhalations given every two to three hours, without interruption of bed rest at night. Since pharmacokinetic studies of aerosolized iloprost were not available when treatment was started, the daily dose was adapted from the initial report by Olschewski et al.<sup>9</sup> The dosage per inhalation and the inhalation interval were determined on the basis of information gained from pulmonary-artery catheter testing at base line. If the pulmonary vascular resistance fell by more than 20 percent after the inhalation of iloprost but returned to base line within less than 60 minutes, the patient was asked to inhale eight times per day. All other patients inhaled six times per day. The dose was increased to 150 µg in six patients after three months.

After familiarization with the equipment, the patients were discharged and were seen every 4 to 12 weeks on an outpatient basis. Readmissions were scheduled after 3 to 12 months for the determination of exercise capacity and repeated right-heart catheterization. The six-minute walk tests during follow-up were performed more than one hour after the last inhalation. All six-minute walk tests were performed over the same route. The catheter tests started early in the morning before the first inhalation of iloprost — that is, between 10 and 12 hours after the last inhalation of iloprost — and the same protocol was used as for the base-line evaluation.

**Statistical Analysis**

All hemodynamic variables and the results of the six-minute walk test are presented as means ±SD. The short-term hemodynamic effects of iloprost challenge were analyzed with Student's paired t-test. The results of the six-minute walk tests and the hemodynamic variables at base line and after 3 and 12 months of treat-

ment with inhaled iloprost were compared by analysis of variance for repeated measurements. If this global test revealed significant differences, the paired t-test was applied to differences between specific groups. Patients who were unable to walk were assigned a score of 0 m on the six-minute walk test. Statistical comparisons of the hemodynamic variables were performed only for the data obtained before the inhalation of iloprost (preinhalation values). Linear regression analysis was used to compare the short-term changes in pulmonary vascular resistance in response to inhaled iloprost at base line with the changes after 12 months of treatment.<sup>16</sup> All tests were two-sided. A P value of less than 0.05 was considered to indicate statistical significance.

**RESULTS**

Between March 1997 and June 1998, treatment with aerosolized iloprost was initiated in 31 patients with primary pulmonary hypertension. None of the patients died within the observation period. Seven patients were excluded from the analysis because follow-up examinations were performed at other centers or by other physicians. The remaining 24 patients received treatment with aerosolized iloprost for at least one year and completed exercise-testing and catheter studies. Fifteen of these patients were women and nine were men. The mean age was 38±12 years (range, 22 to 65). As shown in Table 1, all 24 patients had severe pulmonary hypertension and were in New York Heart Association functional class III (20 patients) or IV (4 patients).

The initial daily dose of aerosolized iloprost was 100 µg in all patients. This dose was subsequently increased to 150 µg in six patients whose exercise capacity did not improve after three months of treatment. In the remaining patients, the dose was kept con-

**TABLE 1. HEMODYNAMIC VARIABLES AND EXERCISE CAPACITY IN 24 PATIENTS WITH PRIMARY PULMONARY HYPERTENSION TREATED WITH INHALED ILOPROST.\***

MEASUREMENT	BASE LINE		3 Mo		12 Mo	
	PREINHALATION	POSTINHALATION	PREINHALATION	POSTINHALATION	PREINHALATION	POSTINHALATION
Heart rate (beats/min)	84±13	84±13	82±15	79±13	82±10	80±10
Mean systemic arterial pressure (mm Hg)	98±14	100±14	93±10†	92±12	90±13†	89±13
Mean pulmonary arterial pressure (mm Hg)	59±10	50±13	52±11†	44±12	52±15†	43±16
Mean right atrial pressure (mm Hg)	8±7	7±6	5±4†	4±4	5±4†	4±4
Cardiac output (liters/min)	3.8±1.4	4.5±1.4	4.0±1.2	4.5±1.2	4.4±1.3†	4.8±1.4
Pulmonary vascular resistance (dyn·sec·cm <sup>-5</sup> )	1205±467	866±415	1001±437†	728±330	925±469†	704±440
Systemic vascular resistance (dyn·sec·cm <sup>-5</sup> )	2088±712	1791±508	1884±506†	1646±397	1660±494††	1534±467
Stroke volume (ml/beat)	46±16	55±16	50±16†	57±15	55±16††	61±19
Mixed venous oxygen saturation (%)	62±8	68±8	65±7†	70±7	67±8†	70±7
6-Minute walk distance (m)	278±96	ND	353±69†	ND	363±135†	ND

\*Values are means ±SD. Preinhalation and postinhalation denote before and immediately after inhalation of iloprost; ND denotes not done.

†P<0.05 for the comparison of preinhalation variables at 3 months or 12 months with preinhalation variables at base line.

††P<0.05 for the comparison of preinhalation variables at 12 months with preinhalation variables at 3 months.

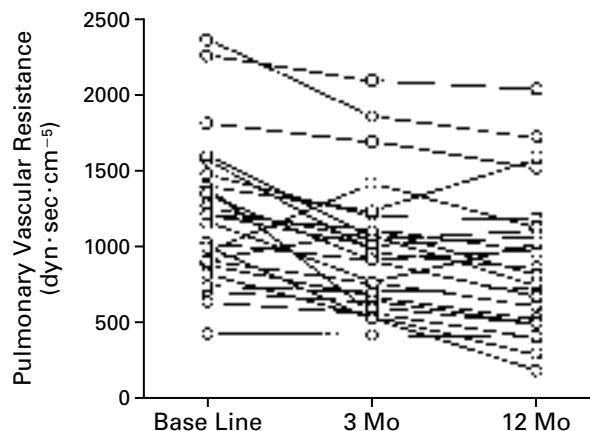
stant throughout the observation period. All patients received anticoagulants. Diuretics were used as clinically indicated. Patients receiving concomitant treatment with digitalis or calcium-channel blockers continued the treatment during the observation period.

As shown in Table 1, results of the six-minute walk test confirmed the presence of severe functional impairment at base line. The distance covered in this test increased significantly, by  $75 \pm 67$  m, after three months of treatment with aerosolized iloprost ( $P < 0.001$ ). This effect was sustained after 12 months, but there was no further significant increase in the walking distance as compared with the results at 3 months.

Challenge with inhaled iloprost caused a short-term decline of  $9 \pm 9.2$  mm Hg in mean pulmonary arterial pressure (mean change,  $-15$  percent [the negative value indicates a decrease];  $P < 0.001$ ), accompanied by an increase in cardiac output of  $0.7 \pm 0.5$  liter per minute (mean change,  $+18$  percent;  $P < 0.001$ ) and a reduction in pulmonary vascular resistance of  $339 \pm 260$  dyn·sec·cm<sup>-5</sup> (mean change,  $-28$  percent;  $P < 0.001$ ) (Table 1). The heart rate and systemic arterial pressure remained practically unaffected. Almost identical short-term hemodynamic effects were obtained with repeated iloprost challenge after 3 and 12 months (Table 1).

As compared with base line, after three months of treatment with aerosolized iloprost there was significant improvement in the values before the inhalation of iloprost for mean pulmonary arterial pressure, mean right atrial pressure, pulmonary vascular resistance, stroke volume, and mixed venous oxygen saturation (Table 1). These effects were sustained at 12 months. At this time, there was also a significant increase in cardiac output as compared with base line, suggesting effective improvement in right ventricular performance with long-term administration of aerosolized iloprost. As compared with base line, preinhalation mean pulmonary arterial pressure was reduced by  $7 \pm 8.7$  mm Hg after 12 months of treatment (mean change,  $-12$  percent;  $P = 0.006$ ), pulmonary vascular resistance by  $280 \pm 323$  dyn·sec·cm<sup>-5</sup> (mean change,  $-23$  percent;  $P < 0.001$ ), and mean right atrial pressure by  $3 \pm 4$  mm Hg ( $P = 0.01$ ). In addition, preinhalation cardiac output increased by  $0.6 \pm 1.3$  liter per minute (mean change,  $+16$  percent;  $P = 0.02$ ), heart rate remained nearly constant, stroke volume rose by  $9 \pm 16$  ml (mean change,  $+20$  percent;  $P = 0.009$ ), and mixed venous oxygen saturation increased by  $5 \pm 8$  percentage points (mean change,  $+8$  percent;  $P = 0.01$ ) (Table 1). Thirteen of the 24 patients (54 percent) had a long-term reduction of at least 20 percent in preinhalation pulmonary vascular resistance (Fig. 1). At all times, there was further improvement in these variables immediately after the inhalation of iloprost (Table 1).

To assess the value of short-term drug challenge with inhaled iloprost for predicting the response to

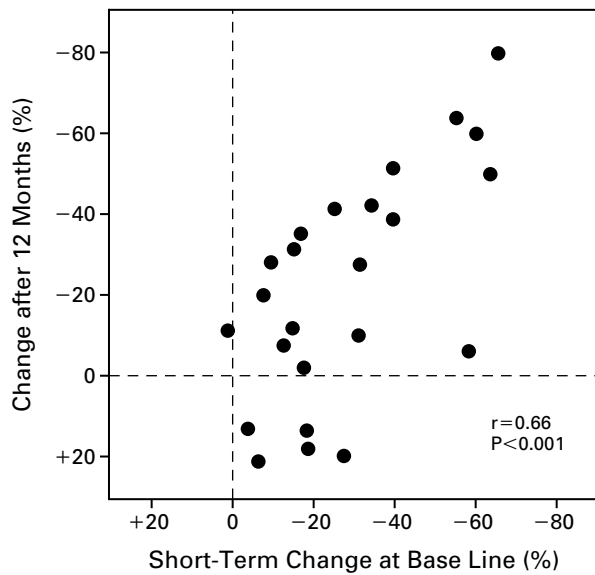


**Figure 1.** Pulmonary Vascular Resistance at Base Line and after 3 Months and 12 Months of Treatment with Aerosolized Iloprost.

The pulmonary vascular resistance declined in all but two patients after 3 months of treatment with iloprost aerosol, followed by a further decline in all but six patients after 12 months. When compared with base-line values, pulmonary vascular resistance was lower after 12 months of treatment with aerosolized iloprost in 19 of 24 patients.

long-term treatment, we compared the short-term changes in pulmonary vascular resistance after inhalation of iloprost at base line with the effects of treatment with aerosolized iloprost on preinhalation pulmonary vascular resistance after 12 months (Fig. 2). In general, patients with a more pronounced short-term response to inhaled iloprost were more likely to have a sustained long-term reduction in pulmonary vascular resistance ( $r = 0.66$ ,  $P < 0.001$ ). However, of the 12 patients in whom the pulmonary vascular resistance dropped by less than 20 percent during short-term drug challenge, 7 had sustained reductions in pulmonary vascular resistance after 12 months of treatment, whereas 1 patient had stable hemodynamic variables and the remaining 4 patients had increased levels of pulmonary vascular resistance, indicating worsening pulmonary hypertension (Fig. 2). Two of the latter patients were eventually switched to continuous intravenous iloprost but did not have clinical improvement; they are currently awaiting lung transplantation.

Treatment with aerosolized iloprost was tolerated well by all patients. Coughing during inhalation was common during the first days of treatment but invariably disappeared spontaneously within the first four weeks. Lung function remained stable in all patients throughout the observation period, as did blood counts, serum electrolyte concentrations, creatinine concentrations, and the results of liver-function tests (data not shown). Five patients reported flushing,



**Figure 2.** Regression Analysis of Short-Term Changes in Pulmonary Vascular Resistance in Response to Inhaled Iloprost at Base Line and Changes in Preinhalation Pulmonary Vascular Resistance after 12 Months of Treatment with Aerosolized Iloprost.

In general, patients with the greatest short-term response to inhaled iloprost had the greatest reduction in pulmonary vascular resistance after 12 months of treatment. However, 7 of 12 patients who had only slight short-term vasodilator responses had considerable reductions in preinhalation pulmonary vascular resistance after long-term treatment with aerosolized iloprost.

headache, and jaw pain at the end of the inhalation, but all of these side effects were rated as mild, and specific treatment or discontinuation of iloprost was not required. Gastrointestinal problems were not reported. Hemodynamic studies revealed a significant decline in systemic arterial pressure and systemic vascular resistance (Table 1), but symptomatic hypotension did not occur in any of the patients. In addition, there were no symptoms, such as dizziness or syncope, suggesting that no rebound phenomena occurred between inhalations or overnight. However, almost all patients described some fluctuations in their exercise capacity, which was usually highest immediately after inhalation and then slowly deteriorated over the following two to three hours until the next inhalation.

## DISCUSSION

Our data show that long-term treatment with aerosolized iloprost has beneficial effects on exercise capacity and hemodynamic variables in patients with primary pulmonary hypertension. The therapeutic efficacy of intravenous epoprostenol in primary pulmonary hypertension has been well described, but the mechanisms by which prostacyclin influences the

course of the disease are incompletely understood. Several studies have shown that the long-term effects of epoprostenol in pulmonary hypertension go beyond vasodilation. Other factors involved may include antithrombotic and antiproliferative effects as well as modulating effects on growth factors and vascular remodeling.<sup>4,7,8,17-19</sup> Some of these effects, such as inhibition of platelet aggregation, could outlast the presence of prostaglandins. In the case of inhaled iloprost, however, it is not yet clear whether plasma concentrations reach sufficient levels to exert an effect on platelet function.

In addition, it is unknown whether prostaglandins need to be administered continuously to exert their therapeutic effect in patients with pulmonary hypertension. The answer to this question, however, is essential for deciding whether to use aerosolized iloprost as an alternative treatment in these patients. Even if the plasma half-life of iloprost is 20 to 30 minutes,<sup>8</sup> the short-term hemodynamic effects of a single inhaled dose almost invariably disappear within an hour after inhalation.<sup>11</sup> Therefore, our observation of improved preinhalation hemodynamic variables (measured after an overnight break in inhalation therapy) after one year of treatment with aerosolized iloprost suggests that mechanisms other than vasodilation contribute to its therapeutic effects. Our findings that the short-term vasodilator response to inhaled iloprost is preserved after 12 months of treatment and that the postinhalation reduction in pulmonary vascular resistance after 12 months exceeded the short-term hemodynamic effects at base line further support this conclusion.

The advantage of inhaled prostanoids over intravenous epoprostenol is that they do not require insertion of a permanent central venous catheter. The main question is whether inhaled iloprost is as effective as intravenous epoprostenol in improving exercise capacity and reducing mortality among patients with primary pulmonary hypertension. Despite the fact that intravenous epoprostenol has been used for more than 10 years to treat pulmonary hypertension, surprisingly little information is available on its long-term effects in this disease. McLaughlin et al. recently described their experience with long-term intravenous epoprostenol therapy in 27 patients with primary pulmonary hypertension.<sup>7</sup> Drug challenge with intravenous adenosine had short-term hemodynamic effects similar to those of inhaled iloprost in our patients. McLaughlin et al. reported a reduction of 53 percent in pulmonary vascular resistance after 12 to 24 months of treatment with intravenous epoprostenol, which clearly exceeded the 23 percent reduction in preinhalation pulmonary vascular resistance in our patients after 1 year of treatment with iloprost aerosol. However, in our patients the postinhalation pulmonary vascular resistance after one year of treatment was reduced by 42 percent from the base-line

preinhalation value, a reduction close to that obtained with intravenous epoprostenol in the study by McLaughlin et al.

The dose of aerosolized iloprost was kept constant at 100  $\mu\text{g}$  per day in the majority of our patients; it was increased to 150  $\mu\text{g}$  per day in six patients whose response was judged unsatisfactory. We do not know, however, whether the regimen we used had optimal efficacy or whether higher doses, different inhalation intervals, or a regimen including regular dose increases would have been better. In the study by McLaughlin et al., the dose of intravenous epoprostenol was increased by an average of 2.4 ng per kilogram of body weight per minute each month, which resulted in a mean dose of approximately 40 ng per kilogram of body weight per minute after 12 to 24 months of treatment.<sup>7</sup> In Germany the annual cost of treating a patient with intravenous epoprostenol at this dose would exceed \$300,000. With the inhalation device used in our hospital, the annual cost of treatment with aerosolized iloprost is about \$50,000 for a daily dose of 100  $\mu\text{g}$  and \$75,000 for a daily dose of 150  $\mu\text{g}$ . With newly developed ultrasonic nebulizers, these costs can be reduced by almost 50 percent.<sup>20</sup>

Inhaled iloprost was generally well tolerated, and no patient discontinued treatment because of side effects. The occurrence of jaw pain and flushing in some patients, as well as a significant, albeit asymptomatic, decline in systemic arterial pressure, suggests that aerosolized iloprost is not a purely selective pulmonary vasodilator, but, rather, that there is some systemic spillover of the drug. There are further unresolved issues regarding the safety of inhaled iloprost. Among these, the possibility of rebound pulmonary hypertension between inhalations and after the overnight break in inhalation therapy is of great concern. However, in our patients there were no clinical or hemodynamic signs of rebound pulmonary hypertension. Rebound phenomena have been recognized as a potentially life-threatening complication in patients receiving intravenous epoprostenol with short-term interruptions of drug delivery.<sup>21</sup> Still, almost all our patients described some fluctuations in their exercise capacity between inhalations. These fluctuations were well tolerated by our patients but could be detrimental in patients with advanced right heart failure. We also found that 5 of the 24 patients (21 percent) had no clinical response to treatment with aerosolized iloprost; it is unclear whether these patients would benefit from a further increase in the dose of inhaled iloprost or whether they should be switched to intravenous epoprostenol.

Overall, our data support the conclusion that aerosolized iloprost is an effective treatment for primary pulmonary hypertension. Currently, phase 3 studies are under way in Europe that are expected to result

in the licensing of inhaled iloprost for the treatment of pulmonary hypertension. With this approach, the options for therapy in advanced pulmonary hypertension increase, but so do the uncertainties about the optimal first-line treatment of patients with this condition. The time has come for studies comparing the long-term effects of intravenous epoprostenol and aerosolized iloprost in patients with primary pulmonary hypertension.

## REFERENCES

- Higenbottam TW, Wheeldon D, Wells E, Wallwork J. Long-term treatment of primary pulmonary hypertension with continuous intravenous epoprostenol (prostacyclin). *Lancet* 1984;1:1046-7.
- Rubin LJ, Mendoza J, Hood M, et al. Treatment of primary pulmonary hypertension with continuous intravenous prostacyclin (epoprostenol): results of a randomized trial. *Ann Intern Med* 1990;112:485-91.
- Barst RJ, Rubin LJ, McGoan MD, Caldwell EJ, Long WA, Levy PS. Survival in primary pulmonary hypertension with long-term continuous intravenous prostacyclin. *Ann Intern Med* 1994;121:409-15.
- Barst RJ, Rubin LJ, Long WA, et al. A comparison of continuous intravenous epoprostenol (prostacyclin) with conventional therapy for primary pulmonary hypertension. *N Engl J Med* 1996;334:296-301.
- Shapiro SM, Oudiz RJ, Cao T, et al. Primary pulmonary hypertension: improved long-term effects and survival with continuous intravenous epoprostenol infusion. *J Am Coll Cardiol* 1997;30:343-9.
- Hinderliter AL, Willis PW IV, Barst RJ, et al. Effects of long-term infusion of prostacyclin (epoprostenol) on echocardiographic measures of right ventricular structure and function in primary pulmonary hypertension. *Circulation* 1997;95:1479-86.
- McLaughlin VV, Genthner DE, Panella MM, Rich S. Reduction in pulmonary vascular resistance with long-term epoprostenol (prostacyclin) therapy in primary pulmonary hypertension. *N Engl J Med* 1998;338:273-7.
- Grant SM, Goa KL. Iloprost: a review of its pharmacodynamic and pharmacokinetic properties, and therapeutic potential in peripheral vascular disease, myocardial ischaemia and extracorporeal circulation procedures. *Drugs* 1992;43:889-924.
- Olschewski H, Walrath D, Schermuly R, Ghofrani A, Grimminger F, Seeger W. Aerosolized prostacyclin and iloprost in severe pulmonary hypertension. *Ann Intern Med* 1996;124:820-4.
- Olschewski H, Ghofrani HA, Schmehl T, et al. Inhaled iloprost to treat severe pulmonary hypertension: an uncontrolled trial. *Ann Intern Med* 2000;132:435-43.
- Hoepfer MM, Olschewski H, Ghofrani HA, et al. A comparison of the acute hemodynamic effects of inhaled nitric oxide and aerosolized iloprost in primary pulmonary hypertension. *J Am Coll Cardiol* 2000;35:176-82.
- Olschewski H, Ghofrani HA, Walrath D, et al. Inhaled prostacyclin and iloprost in severe pulmonary hypertension secondary to lung fibrosis. *Am J Respir Crit Care Med* 1999;160:600-7.
- Rich S, Dantzker DR, Ayres SM, et al. Primary pulmonary hypertension: a national prospective study. *Ann Intern Med* 1987;107:216-23.
- Guyatt GH, Sullivan MJ, Thompson PJ, et al. The 6-minute walk: a new measure of exercise capacity in patients with chronic heart failure. *CMAJ* 1985;132:919-23.
- Hoepfer MM, Maier R, Tongers J, et al. Determination of cardiac output by the Fick method, thermodilution, and acetylene rebreathing in pulmonary hypertension. *Am J Respir Crit Care Med* 1999;160:535-41.
- Rosner B. *Fundamentals of biostatistics*. 4th ed. Belmont, Calif.: Duxbury Press, 1995.
- Hoepfer MM, Voelkel NF, Bates TO, et al. Prostaglandins induce vascular endothelial growth factor in a human monocytic cell line and rat lungs via cAMP. *Am J Respir Cell Mol Biol* 1997;17:748-56.
- Fishman AP. Pulmonary hypertension — beyond vasodilator therapy. *N Engl J Med* 1998;338:321-2.
- Idem*. Epoprostenol (prostacyclin) and pulmonary hypertension. *Ann Intern Med* 2000;132:500-2.
- Gessler T, Schmehl T, Seeger W. Comparison of two inhalation systems for Iloprost-aerosol therapy in pulmonary hypertension. *Am J Respir Crit Care Med* 1999;159:Suppl:A159. abstract.
- Rubin LJ. Primary pulmonary hypertension. *N Engl J Med* 1997;336:111-7.