

## ABC of clinical electrocardiography

### Conditions affecting the right side of the heart

Richard A Harrigan, Kevin Jones

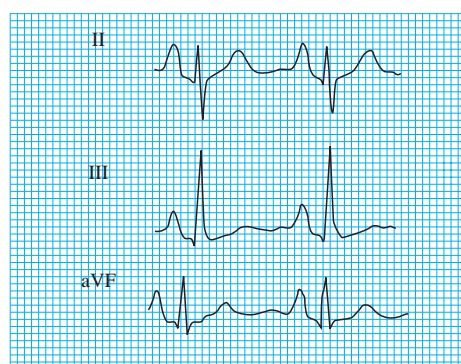
Many diseases of the right side of the heart are associated with electrocardiographic abnormalities. Electrocardiography is neither a sensitive nor specific tool for diagnosing conditions such as right atrial enlargement, right ventricular hypertrophy, or pulmonary hypertension. However, an awareness of the electrocardiographic abnormalities associated with these conditions may support the patient's clinical assessment and may prevent the changes on the electrocardiogram from being wrongly attributed to other conditions, such as ischaemia.

This article discusses right atrial enlargement, right ventricular hypertrophy, and the electrocardiographic changes associated with chronic obstructive pulmonary disease, pulmonary embolus, acute right heart strain, and valvular heart disease

#### Right atrial enlargement

The forces generated by right atrial depolarisation are directed anteriorly and inferiorly and produce the early part of the P wave. Right atrial hypertrophy or dilatation is therefore associated with tall P waves in the anterior and inferior leads, though the overall duration of the P wave is not usually prolonged. A tall P wave (height  $\geq 2.5$  mm) in leads II, III, and aVF is known as the P pulmonale.

The electrocardiographic changes suggesting right atrial enlargement often correlate poorly with the clinical and pathological findings. Right atrial enlargement is associated with chronic obstructive pulmonary disease, pulmonary hypertension, and congenital heart disease—for example, pulmonary stenosis and tetralogy of Fallot. In practice, most cases of right atrial enlargement are associated with right ventricular hypertrophy, and this may be reflected in the electrocardiogram. The electrocardiographic features of right atrial enlargement without coexisting right ventricular hypertrophy are seen in patients with tricuspid stenosis. P pulmonale may appear transiently in patients with acute pulmonary embolism.



Large P waves in leads II, III, and aVF (P pulmonale)

#### Right ventricular hypertrophy

The forces generated by right ventricular depolarisation are directed rightwards and anteriorly and are almost completely masked by the dominant forces of left ventricular depolarisation. In the presence of right ventricular hypertrophy the forces of depolarisation increase, and if the hypertrophy is severe these forces may dominate on the electrocardiogram.

The electrocardiogram is a relatively insensitive indicator of the presence of right ventricular hypertrophy, and in mild cases of right ventricular hypertrophy the trace will be normal.

#### Diagnostic criteria for right ventricular hypertrophy

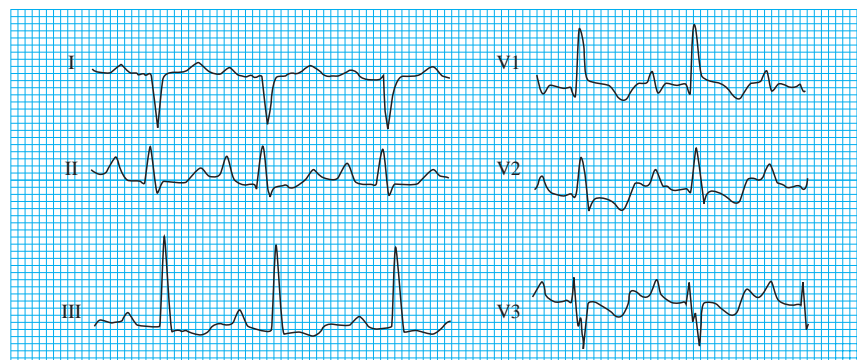
(Provided the QRS duration is less than 0.12 s)

- Right axis deviation of  $+110^\circ$  or more
- Dominant R wave in lead V1
- R wave in lead V1  $\geq 7$  mm

#### Supporting criteria

- ST segment depression and T wave inversion in leads V1 to V4
- Deep S waves in leads V5, V6, I, and aVL

Right ventricular hypertrophy is associated with pulmonary hypertension, mitral stenosis, and, less commonly, conditions such as pulmonary stenosis and congenital heart disease



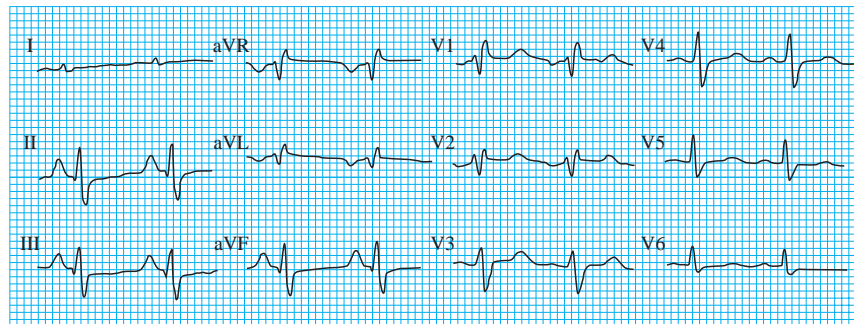
Right ventricular hypertrophy secondary to pulmonary stenosis (note the dominant R wave in lead V1, presence of right atrial hypertrophy, right axis deviation, and T wave inversion in leads V1 to V3)

Lead V1 lies closest to the right ventricular myocardium and is therefore best placed to detect the changes of right ventricular hypertrophy, and a dominant R wave in lead V1 is observed. The increased rightward forces are reflected in the limb leads, in the form of right axis deviation. Secondary changes may be observed in the right precordial chest leads, where ST segment depression and T wave inversion are seen.

A dominant R wave in lead V1 can occur in other conditions, but the absence of right axis deviation allows these conditions to be differentiated from right ventricular hypertrophy. Isolated right axis deviation is also associated with a range of conditions.

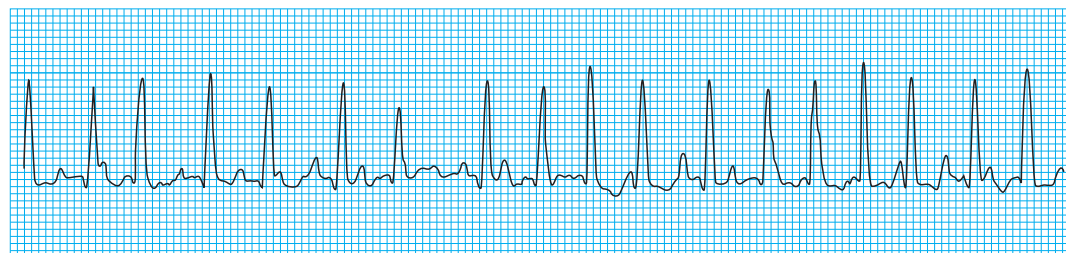
## Chronic obstructive pulmonary disease

In chronic obstructive pulmonary disease, hyperinflation of the lungs leads to depression of the diaphragm, and this is associated with clockwise rotation of the heart along its longitudinal axis. This clockwise rotation means that the transitional zone (defined as the progression of rS to qR in the chest leads) shifts towards the left with persistence of an rS pattern as far as V5 or even V6. This may give rise to a “pseudoinfarct” pattern, with deep S waves in the right precordial leads simulating the appearance of the QS waves and poor R wave progression seen in anterior myocardial infarction. The amplitude of the QRS complexes may be small in patients with chronic obstructive pulmonary disease as the hyperinflated lungs are poor electrical conductors.



Chronic obstructive pulmonary disease (note the P pulmonale, low amplitude QRS complexes, and poor R wave progression)

Cardiac arrhythmias may occur in patients with chronic obstructive pulmonary disease, particularly in association with an acute respiratory tract infection, respiratory failure, or pulmonary embolism. Arrhythmias are sometimes the result of the underlying disease process but may also occur as side effects of the drugs used to treat the disease.



Multifocal atrial tachycardia

The arrhythmias are mostly supraventricular in origin and include atrial extrasystoles, atrial fibrillation or flutter, and multifocal atrial tachycardia. Ventricular extrasystoles and ventricular tachycardia may also occur.

### Conditions associated with tall R wave in lead V1

- Right ventricular hypertrophy
- Posterior myocardial infarction
- Type A Wolff-Parkinson-White syndrome
- Right bundle branch block

*A tall R wave in lead V1 is normal in children and young adults*

### Conditions associated with right axis deviation

- Right ventricular hypertrophy
- Left posterior hemiblock
- Lateral myocardial infarction
- Acute right heart strain

*Right axis deviation is normal in infants and children*

**About three quarters of patients with chronic obstructive pulmonary disease have electrocardiographic abnormalities. P pulmonale is often but not invariably present and may occur with or without clinical evidence of cor pulmonale**

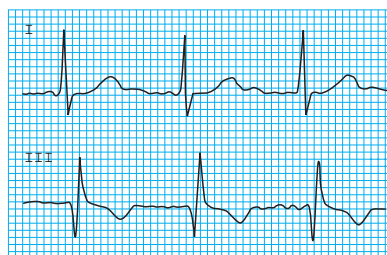**In chronic obstructive pulmonary disease the electrocardiographic signs of right ventricular hypertrophy may be present, indicating the presence of cor pulmonale**

## Acute pulmonary embolism

The electrocardiographic features of acute pulmonary embolism depend on the size of the embolus and its haemodynamic effects and on the underlying cardiopulmonary reserve of the patient. The timing and frequency of the electrocardiographic recording is also important as changes may be transient. Patients who present with a small pulmonary embolus are likely to have a normal electrocardiogram or a trace showing only sinus tachycardia.

If the embolus is large and associated with pulmonary artery obstruction, acute right ventricular dilatation may occur. This may produce an S wave in lead I and a Q wave in lead III. T wave inversion in lead III may also be present, producing the well known S1, Q3, T3 pattern.

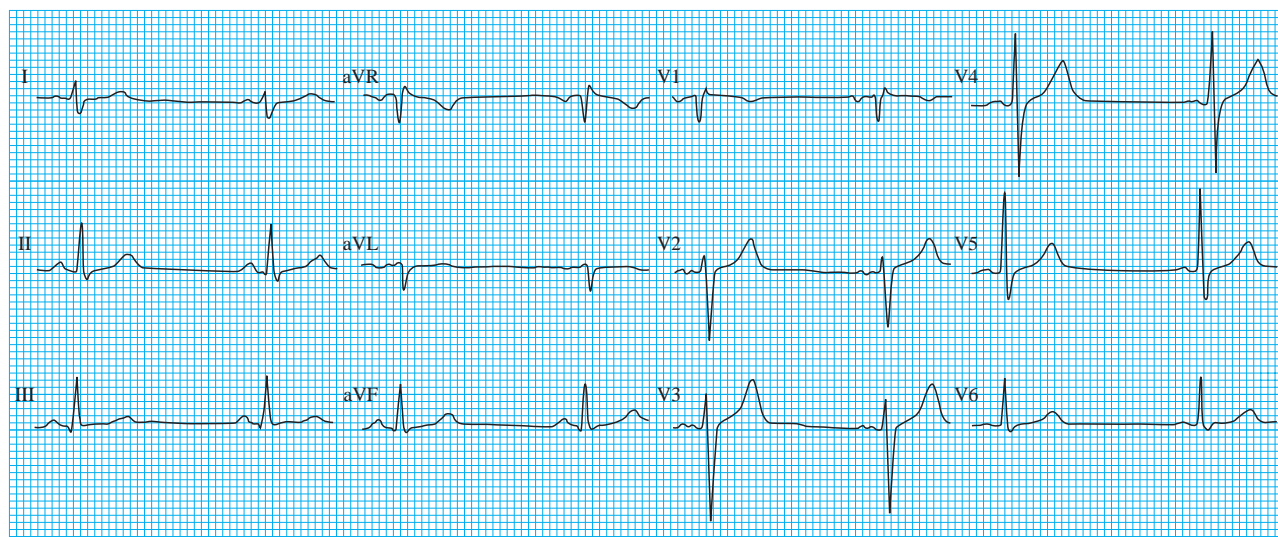
**The S1, Q3, T3 pattern is seen in about 12% of patients with a massive pulmonary embolus**



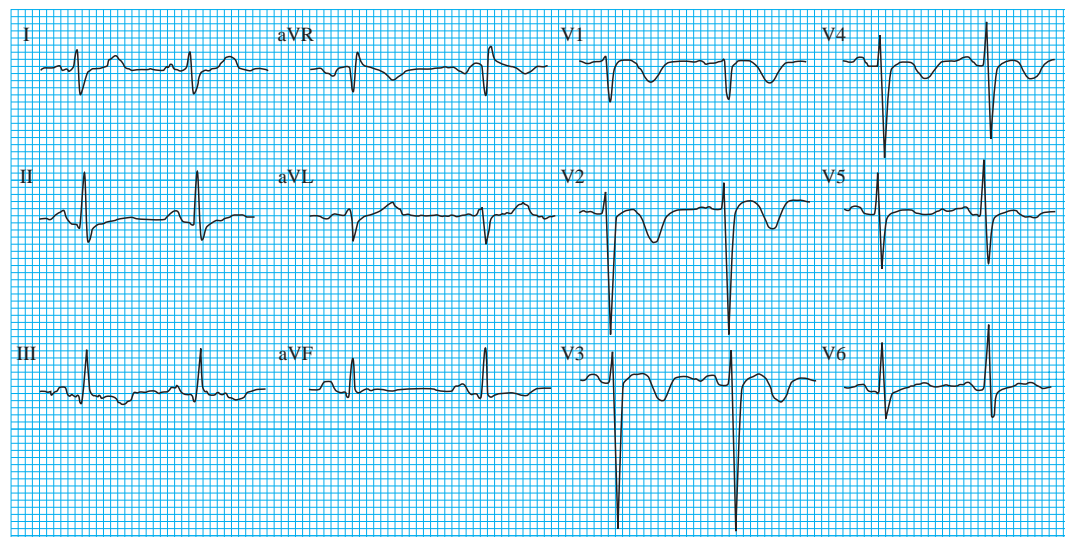
Sinus tachycardia and S1, Q3, T3 pattern in patient with pulmonary embolus

**Right ventricular dilatation may lead to right sided conduction delays, which manifest as incomplete or complete right bundle branch block. There may be some rightward shift of the frontal plane QRS axis.**

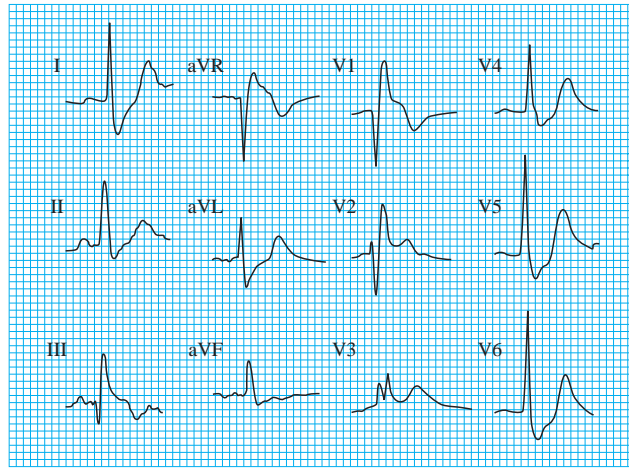
**Right atrial dilatation may lead to prominent P waves in the inferior leads. Atrial arrhythmias including flutter and fibrillation are common, and T wave inversion in the right precordial leads may also occur**



Preoperative electrocardiogram in otherwise healthy 38 year old man



Acute pulmonary embolism: 10 days postoperatively the same patient developed acute dyspnoea and hypotension (note the T wave inversion in the right precordial leads and lead III)



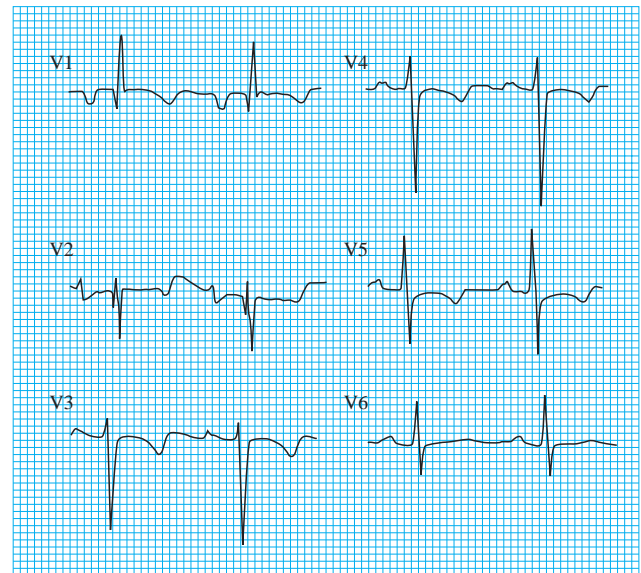
S1, Q3, T3 pattern and right bundle branch block in patient with pulmonary embolus

### Electrocardiographic abnormalities found in acute pulmonary embolism

- Sinus tachycardia
- Atrial flutter or fibrillation
- S1, Q3, T3 pattern
- Right bundle branch block (incomplete or complete)
- T wave inversion in the right precordial leads
- P pulmonale
- Right axis deviation

## Acute right heart strain

When the electrocardiogram shows features of right ventricular hypertrophy accompanied by ST segment depression and T wave inversion, a ventricular "strain" pattern is said to exist. Ventricular strain is seen mainly in leads V1 and V2. The mechanism is unclear. A strain pattern is sometimes seen in acute massive pulmonary embolism but is also seen in patients with right ventricular hypertrophy in the absence of any detectable stress on the ventricle. Both pneumothorax and massive pleural effusion with acute right ventricular dilatation may also produce a strain pattern.



Example of right heart strain: right ventricular hypertrophy with widespread T wave inversion in chest leads

## Right sided valvular problems

### Tricuspid stenosis

Tricuspid stenosis is a rare disorder and is usually associated with rheumatic heart disease. It appears in the electrocardiogram as P pulmonale. It generally occurs in association with mitral valve disease, and therefore the electrocardiogram often shows evidence of biatrial enlargement, indicated by a large biphasic P wave in lead V1 with an initial positive deflection followed by a terminal negative deflection.

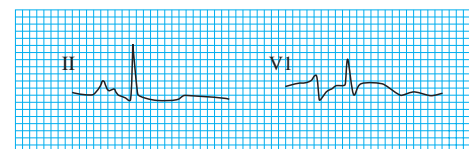
### Tricuspid regurgitation

The electrocardiogram is an unhelpful tool for diagnosing tricuspid regurgitation and generally shows the features of the underlying cardiac disease. The electrocardiographic manifestations of tricuspid regurgitation are non-specific and include incomplete right bundle branch block and atrial fibrillation.

### Pulmonary stenosis

Pulmonary stenosis leads to pressure overload in the right atrium and ventricle. The electrocardiogram may be completely normal in the presence of mild pulmonary stenosis. More severe lesions are associated with electrocardiographic features of right atrial and ventricular hypertrophy, with tall P waves, marked right axis deviation, and a tall R wave in lead V1.

Kevin Jones is consultant chest physician at Bolton Royal Hospital. Richard A Harrigan is associate professor of emergency medicine at Temple University School of Medicine and associate research director, division of emergency medicine, Temple University Hospital, Philadelphia, PA, USA.



Biatrial abnormality

The ABC of clinical electrocardiography is edited by Francis Morris, consultant in emergency medicine at the Northern General Hospital, Sheffield; June Edhouse, consultant in emergency medicine, Stepping Hill Hospital, Stockport; William J Brady, associate professor, programme director, and vice chair, department of emergency medicine, University of Virginia, Charlottesville, VA, USA; and John Camm, professor of clinical cardiology, St George's Hospital Medical School, London. The series will be published as a book in the summer.