

*ABC of clinical electrocardiography***Bradycardias and atrioventricular conduction block**

David Da Costa, William J Brady, June Edhouse

By arbitrary definition, a bradycardia is a heart rate of < 60 beats/min. A bradycardia may be a normal physiological phenomenon or result from a cardiac or non-cardiac disorder.

Sinus bradycardia

Sinus bradycardia is common in normal individuals during sleep and in those with high vagal tone, such as athletes and young healthy adults. The electrocardiogram shows a P wave before every QRS complex, with a normal P wave axis (that is, upright P wave in lead II). The PR interval is at least 0.12 s.

The commonest pathological cause of sinus bradycardia is acute myocardial infarction. Sinus bradycardia is particularly associated with inferior myocardial infarction as the inferior myocardial wall and the sinoatrial and atrioventricular nodes are usually all supplied by the right coronary artery.

Sick sinus syndrome

Sick sinus syndrome is the result of dysfunction of the sinoatrial node, with impairment of its ability to generate and conduct impulses. It usually results from idiopathic fibrosis of the node but is also associated with myocardial ischaemia, digoxin, and cardiac surgery.

The possible electrocardiographic features include persistent sinus bradycardia, periods of sinoatrial block, sinus arrest, junctional or ventricular escape rhythms, tachycardia-bradycardia syndrome, paroxysmal atrial flutter, and atrial fibrillation. The commonest electrocardiographic feature is an inappropriate, persistent, and often severe sinus bradycardia.

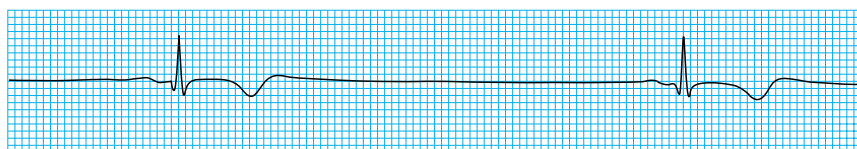
Many patients tolerate heart rates of 40 beats/min surprisingly well, but at lower rates symptoms are likely to include dizziness, near syncope, syncope, ischaemic chest pain, Stokes-Adams attacks, and hypoxic seizures

Pathological causes of sinus bradycardia

- Acute myocardial infarction
- Drugs—for example, β blockers, digoxin, amiodarone
- Obstructive jaundice
- Raised intracranial pressure
- Sick sinus syndrome
- Hypothermia
- Hypothyroidism

Conditions associated with sinoatrial node dysfunction

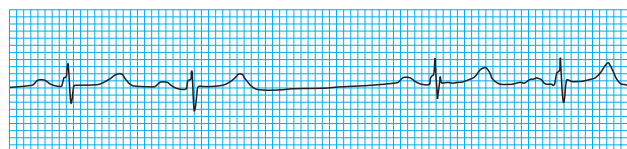
- Age
- Idiopathic fibrosis
- Ischaemia, including myocardial infarction
- High vagal tone
- Myocarditis
- Digoxin toxicity



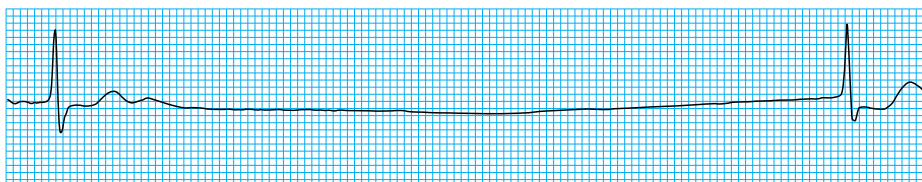
Severe sinus bradycardia

Sinoatrial block is characterised by a transient failure of impulse conduction to the atrial myocardium, resulting in intermittent pauses between P waves. The pauses are the length of two or more P-P intervals.

Sinus arrest occurs when there is transient cessation of impulse formation at the sinoatrial node; it manifests as a prolonged pause without P wave activity. The pause is unrelated to the length of the P-P cycle.



Sinoatrial block (note the pause is twice the P-P interval)



Sinus arrest with pause of 4.4 s before generation and conduction of a junctional escape beat

Escape rhythms are the result of spontaneous activity from a subsidiary pacemaker, located in the atria, atrioventricular junction, or ventricles. They take over when normal impulse formation or conduction fails and may be associated with any profound bradycardia.

A junctional escape beat has a normal QRS complex shape with a rate of 40-60 beats/min. A ventricular escape rhythm has broad complexes and is slow (15-40 beats/min)

Atrioventricular conduction block

Atrioventricular conduction can be delayed, intermittently blocked, or completely blocked—classified correspondingly as first, second, or third degree block.

First degree block

In first degree block there is a delay in conduction of the atrial impulse to the ventricles, usually at the level of the atrioventricular node. This results in prolongation of the PR interval to >0.2 s. A QRS complex follows each P wave, and the PR interval remains constant.

Second degree block

In second degree block there is intermittent failure of conduction between the atria and ventricles. Some P waves are not followed by a QRS complex.

There are three types of second degree block. Mobitz type I block (Wenckebach phenomenon) is usually at the level of the atrioventricular node, producing intermittent failure of transmission of the atrial impulse to the ventricles. The initial PR interval is normal but progressively lengthens with each successive beat until eventually atrioventricular transmission is blocked completely and the P wave is not followed by a QRS complex. The PR interval then returns to normal, and the cycle repeats.

Mobitz type II block is less common but is more likely to produce symptoms. There is intermittent failure of conduction of P waves. The PR interval is constant, though it may be normal or prolonged. The block is often at the level of the bundle branches and is therefore associated with wide QRS complexes. 2:1 atrioventricular block is difficult to classify, but it is usually a Wenckebach variant. High degree atrioventricular block, which occurs when a QRS complex is seen only after every three, four, or more P waves, may progress to complete third degree atrioventricular block.

Third degree block

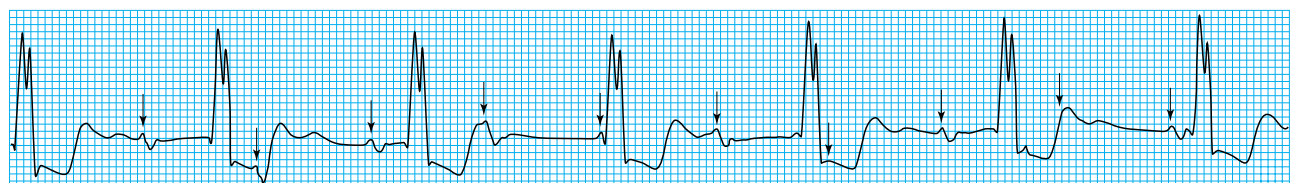
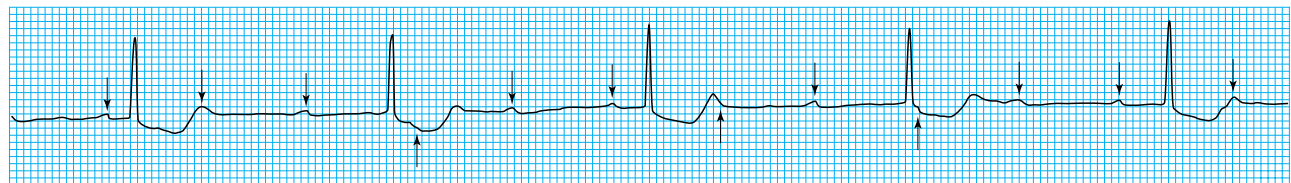
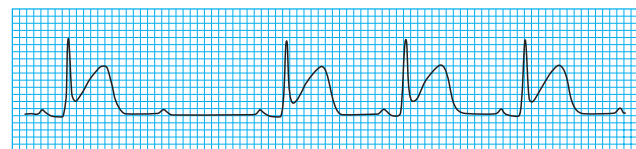
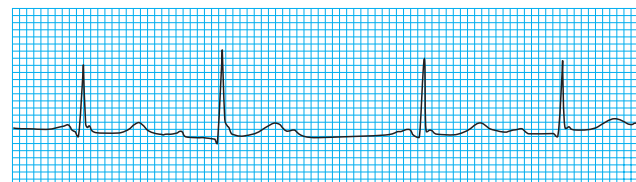
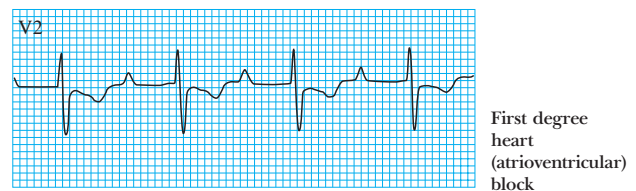
In third degree block there is complete failure of conduction between the atria and ventricles, with complete independence of atrial and ventricular contractions. The P waves bear no relation to the QRS complexes and usually proceed at a faster rate.

Tachycardia-bradycardia syndrome

- Common in sick sinus syndrome
- Characterised by bursts of atrial tachycardia interspersed with periods of bradycardia
- Paroxysmal atrial flutter or fibrillation may also occur, and cardioversion may be followed by a severe bradycardia

Causes of atrioventricular conduction block

- Myocardial ischaemia or infarction
- Degeneration of the His-Purkinje system
- Infection—for example, Lyme disease, diphtheria
- Immunological disorders—for example, systemic lupus erythematosus
- Surgery
- Congenital disorders



Third degree heart block. A pacemaker in the bundle of His produces a narrow QRS complex (top), whereas more distal pacemakers tend to produce broader complexes (bottom). Arrows show P waves

A subsidiary pacemaker triggers ventricular contractions, though occasionally no escape rhythm occurs and asystolic arrest ensues. The rate and QRS morphology of the escape rhythm vary depending on the site of the pacemaker.

Bundle branch block and fascicular block

The bundle of His divides into the right and left bundle branches. The left bundle branch then splits into anterior and posterior hemifascicles. Conduction blocks in any of these structures produce characteristic electrocardiographic changes.

Right bundle branch block

In most cases right bundle branch block has a pathological cause though it is also seen in healthy individuals.

When conduction in the right bundle branch is blocked, depolarisation of the right ventricle is delayed. The left ventricle depolarises in the normal way and thus the early part of the QRS complex appears normal. The wave of depolarisation then spreads to the right ventricle through non-specialised conducting tissue, with slow depolarisation of the right ventricle in a left to right direction. As left ventricular depolarisation is complete, the forces of right ventricular depolarisation are unopposed. Thus the later part of the QRS complex is abnormal; the right precordial leads have a prominent and late R wave, and the left precordial and limb leads have a terminal S wave. These terminal deflections are wide and slurred. Abnormal ventricular depolarisation is associated with secondary repolarisation changes, giving rise to changes in the ST-T waves in the right chest leads.

Diagnostic criteria for right bundle branch block

- QRS duration ≥ 0.12 s
- A secondary R wave (R') in V1 or V2
- Wide slurred S wave in leads I, V5, and V6

Associated features

- ST segment depression and T wave inversion in the right precordial leads

Left bundle branch block

Left bundle branch block is most commonly caused by coronary artery disease, hypertensive heart disease, or dilated cardiomyopathy. It is unusual for left bundle branch block to exist in the absence of organic disease.

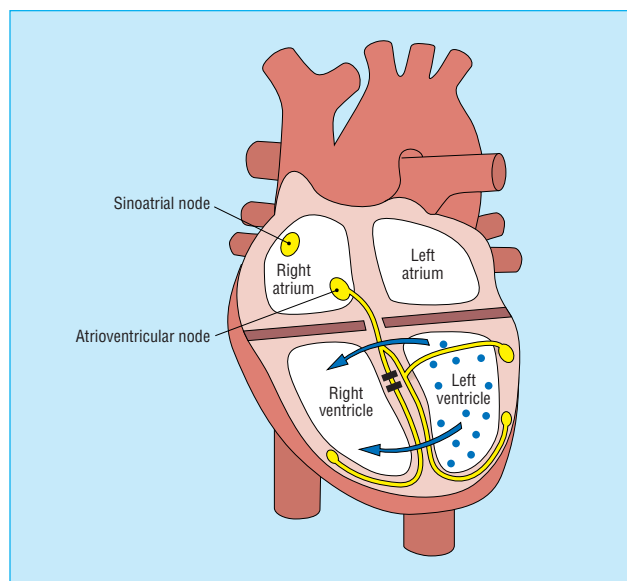
The left bundle branch is supplied by both the anterior descending artery (a branch of the left coronary artery) and the right coronary artery. Thus patients who develop left bundle branch block generally have extensive disease. This type of block is seen in 2-4% of patients with acute myocardial infarction and is usually associated with anterior infarction.

Diagnostic criteria for left bundle branch block

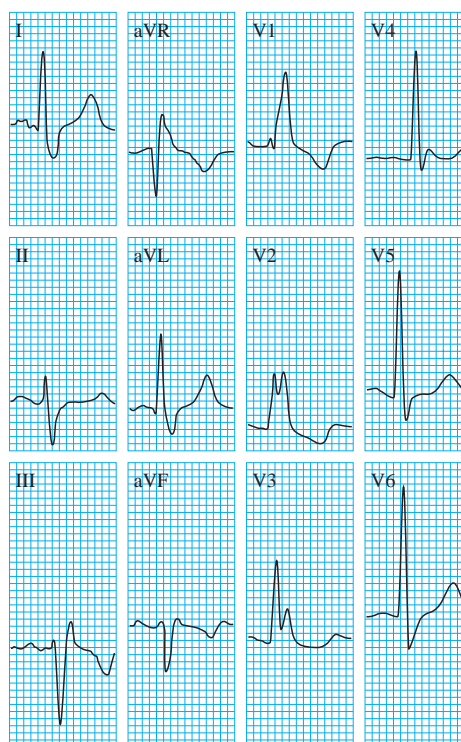
- QRS duration of ≥ 0.12 s
 - Broad monophasic R wave in leads I, V5, and V6
 - Absence of Q waves in leads V5 and V6
- #### Associated features
- Displacement of ST segment and T wave in an opposite direction to the dominant deflection of the QRS complex (appropriate discordance)
 - Poor R wave progression in the chest leads
 - RS complex, rather than monophasic complex, in leads V5 and V6
 - Left axis deviation—common but not invariable finding

Conditions associated with right bundle branch block

- Rheumatic heart disease
- Cor pulmonale/right ventricular hypertrophy
- Myocarditis or cardiomyopathy
- Ischaemic heart disease
- Degenerative disease of the conduction system
- Pulmonary embolus
- Congenital heart disease—for example, in atrial septal defects



Right bundle branch block, showing the wave of depolarisation spreading to the right ventricle through non-specialised conducting tissue



Right bundle branch block

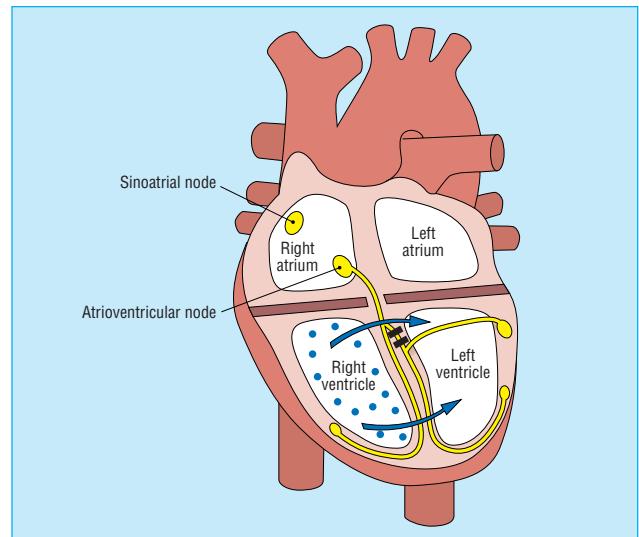
In the normal heart, septal depolarisation proceeds from left to right, producing Q waves in the left chest leads (septal Q waves). In left bundle branch block the direction of depolarisation of the intraventricular septum is reversed; the septal Q waves are lost and replaced with R waves. The delay in left ventricular depolarisation increases the duration of the QRS complex to >0.12 s. Abnormal ventricular depolarisation leads to secondary repolarisation changes. ST segment depression and T wave inversion are seen in leads with a dominant R wave. ST segment elevation and positive T waves are seen in leads with a dominant S wave. Thus there is discordance between the QRS complex and the ST segment and T wave.

Fascicular blocks

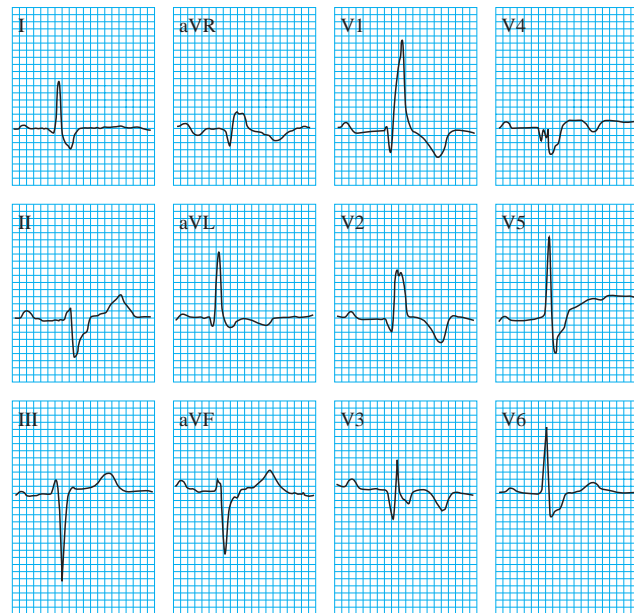
Block of the left anterior and posterior hemifascicles gives rise to the hemiblocks. Left anterior hemiblock is characterised by a mean frontal plane axis more leftward than -30° (abnormal left axis deviation) in the absence of an inferior myocardial infarction or other cause of left axis deviation. Left posterior hemiblock is characterised by a mean frontal plane axis of $>90^\circ$ in the absence of other causes of right axis deviation.

Bifascicular block is the combination of right bundle branch block and left anterior or posterior hemiblock. The electrocardiogram shows right bundle branch block with left or right axis deviation. Right bundle branch block with left anterior hemiblock is the commonest type of bifascicular block. The left posterior fascicle is fairly stout and more resistant to damage, so right bundle branch block with left posterior hemiblock is rarely seen.

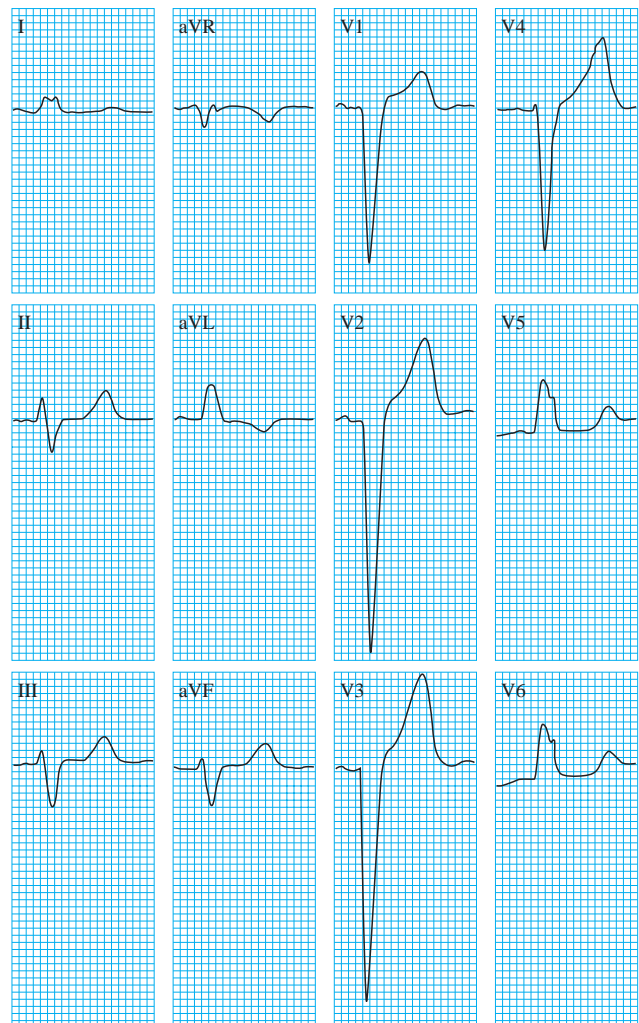
Trifascicular block is present when bifascicular block is associated with first degree heart block. If conduction in the dysfunctional fascicle also fails completely, complete heart block ensues.



Left bundle branch block, showing depolarisation spreading from the right to left ventricle



Trifascicular block (right bundle branch block, left anterior hemiblock, and first degree heart block)



Left bundle branch block

The ABC of clinical electrocardiography is edited by Francis Morris, consultant in emergency medicine at the Northern General Hospital, Sheffield; June Edhouse, consultant in emergency medicine, Stepping Hill Hospital, Stockport; William J Brady, associate professor, programme director, and vice chair, department of emergency medicine, University of Virginia, Charlottesville, VA, USA; and John Camm, professor of clinical cardiology, St George's Hospital Medical School, London. The series will be published as a book in the summer.

David Da Costa is consultant physician at the Northern General Hospital, Sheffield.