

*Medical Progress***CONGENITAL HEART DISEASE
IN ADULTS****First of Two Parts**M. ELIZABETH BRICKNER, M.D., L. DAVID HILLIS, M.D.,
AND RICHARD A. LANGE, M.D.

OVER the past 20 to 30 years, major advances have been made in the diagnosis and treatment of congenital heart disease in children. As a result, many children with such disease now survive to adulthood. In the United States alone, the population of adults with congenital heart disease, either surgically corrected or uncorrected, is estimated to be increasing at a rate of about 5 percent per year; this year there will be almost 1 million such patients.¹ This two-part review discusses the more common acyanotic and cyanotic congenital heart conditions that physicians who care for adults are likely to encounter.

ACYANOTIC CONDITIONS**Atrial Septal Defect**

Atrial septal defect accounts for about one third of the cases of congenital heart disease detected in adults. It occurs in women two to three times as often as in men.^{2,3} Anatomically, it may take the form of ostium secundum, in the region of the fossa ovalis; ostium primum, in the lower part of the atrial septum; or sinus venosus, in the upper atrial septum. Ostium secundum defects make up 75 percent of all atrial septal defects, ostium primum defects make up 15 percent, and sinus venosus defects make up 10 percent. Additional cardiac abnormalities may occur with each type of defect; these include mitral-valve prolapse (with ostium secundum defects),⁴ mitral regurgitation (due to a cleft in the anterior mitral-valve leaflet, which occurs with ostium primum defects), and par-

tial anomalous drainage of the pulmonary veins into the right atrium or venae cavae (with sinus venosus defects).⁵ Although most atrial septal defects result from spontaneous genetic mutations, some are inherited.⁶⁻⁹

Regardless of anatomical location, the physiologic consequences of atrial septal defects are the result of the shunting of blood from one atrium to the other; the direction and magnitude of shunting are determined by the size of the defect and the relative compliance of the ventricles. A small defect (less than 0.5 cm in diameter) is associated with a small shunt and no hemodynamic sequelae. A sizable defect (more than 2 cm in diameter) may be associated with a large shunt, with substantial hemodynamic consequences. In most adults with atrial septal defects, the right ventricle is more compliant than the left; as a result, left atrial blood is shunted to the right atrium, causing increased pulmonary blood flow and dilatation of the atria, right ventricle, and pulmonary arteries (Fig. 1). Eventually, if the right ventricle fails or its compliance declines, the left-to-right shunting diminishes in magnitude, and right-to-left shunting may even occur.

In a patient with a large atrial septal defect, a right ventricular or pulmonary arterial impulse may be palpable. The first heart sound is normal, and there is wide and fixed splitting of the second heart sound. The splitting of the second heart sound is fixed because phasic changes in systemic venous return to the right atrium during respiration are accompanied by reciprocal changes in the volume of shunted blood from the left atrium to the right atrium, thereby minimizing the respiratory changes in right and left ventricular stroke volumes that are normally responsible for physiologic splitting.¹⁰ A systolic ejection murmur, audible in the second left intercostal space, peaks in mid-systole, ends before the second heart sound, and is usually so soft that it is mistaken for an "innocent" flow murmur. Flow across the atrial septal defect itself does not produce a murmur.

Electrocardiographically, a patient with atrial septal defect often has right-axis deviation and incomplete right bundle-branch block. Left-axis deviation occurs with ostium primum defects. A junctional or low atrial rhythm (inverted P waves in the inferior leads) occurs with sinus venosus defects. A patient with an atrial septal defect usually has normal sinus rhythm for the first three decades of life, after which atrial arrhythmias, including atrial fibrillation and supraventricular tachycardia, may appear.¹¹ On chest radiography, the patient has prominent pulmonary arteries and a peripheral pulmonary vascular pattern

From the Department of Internal Medicine, Cardiovascular Division, University of Texas Southwestern Medical Center, Dallas. Address reprint requests to Dr. Hillis at Rm. CS7.102, University of Texas Southwestern Medical Center, 5323 Harry Hines Blvd., Dallas, TX 75235-9047.

©2000, Massachusetts Medical Society.

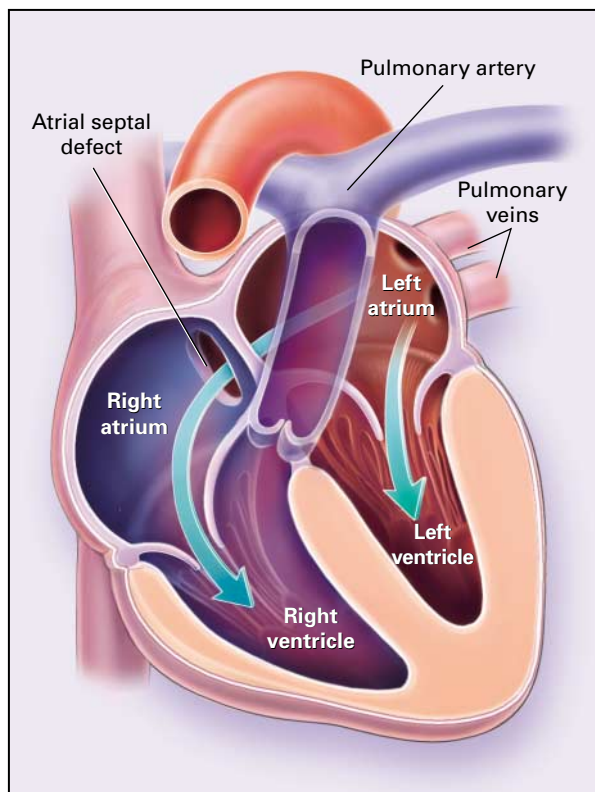


Figure 1. Atrial Septal Defect with Resultant Left-to-Right Shunting.

Blood from the pulmonary veins enters the left atrium, after which some of it crosses the atrial septal defect into the right atrium and ventricle (longer arrow).

of “shunt vascularity” (in which the small pulmonary arteries are especially well visualized in the periphery of both lungs).

Transthoracic echocardiography may reveal dilatation of the atria and right ventricle. Ostium primum or ostium secundum defects are often visualized directly, but transthoracic echocardiography usually does not identify sinus venosus defects.¹² The sensitivity of echocardiography may be enhanced by injecting microbubbles of air in solution into a peripheral vein, after which the movement of some of the bubbles across the defect into the left atrium can be visualized. Transesophageal and Doppler color-flow echocardiography are particularly useful in detecting and determining the location of atrial septal defects and in identifying sinus venosus defects and anomalous pulmonary venous drainage. Although echocardiography may provide enough information to guide the management of an atrial septal defect, catheterization may be required to determine the magnitude and direction of shunting, as well as whether pulmonary hypertension is present and, if so, its severity.

Since atrial septal defects initially produce no symp-

oms and are not accompanied by striking abnormalities on physical examination, they often remain undetected for years.^{3,13,14} A small defect with minimal left-to-right shunting (characterized by a ratio of pulmonary to systemic flow of less than 1.5) usually causes no symptoms or hemodynamic abnormalities and therefore does not require closure. Patients with moderate or large atrial septal defects often have no symptoms until the third or fourth decades of life despite substantial left-to-right shunting (characterized by a ratio of pulmonary to systemic flow of 1.5 or more). Over the years, the increased volume of blood flowing through the chambers of the right side of the heart usually causes right ventricular dilatation and failure.^{3,14-16} Obstructive pulmonary vascular disease (Eisenmenger’s syndrome) occurs rarely in adults with atrial septal defect.¹⁴

A symptomatic patient with an atrial septal defect typically reports fatigue or dyspnea on exertion. Alternatively, the development of such sequelae as supraventricular arrhythmias, right heart failure, paradoxical embolism, or recurrent pulmonary infections may prompt the patient to seek medical attention. Although a few patients with an unrepaired atrial septal defect have survived into the eighth or ninth decade of life,¹⁷ those with sizable shunts often die of right ventricular failure or arrhythmia in their 30s or 40s.^{3,13-15}

An atrial septal defect with a ratio of pulmonary to systemic flow of 1.5 or more should be closed surgically to prevent right ventricular dysfunction.¹⁸⁻²⁰ Surgical closure is not recommended for patients with irreversible pulmonary vascular disease and pulmonary hypertension.²¹ Although devices for percutaneous atrial septal closure are under investigation,^{22,23} their safety and efficacy are unknown. Prophylaxis against infective endocarditis is not recommended for patients with atrial septal defects (repaired or unrepaired) unless a concomitant valvular abnormality (e.g., mitral-valve cleft or prolapse) is present.²⁴

Ventricular Septal Defect

Ventricular septal defect is the most common congenital cardiac abnormality in infants and children. It occurs with similar frequency in boys and girls. Twenty-five to 40 percent of such defects close spontaneously by the time the child is 2 years old; 90 percent of those that eventually close do so by the time the child is 10.^{11,25} Anatomically, 70 percent are located in the membranous portion of the interventricular septum, 20 percent in the muscular portion of the septum, 5 percent just below the aortic valve (thereby undermining the valve annulus and causing regurgitation), and 5 percent near the junction of the mitral and tricuspid valves (so-called atrioventricular canal defects).²⁶

The physiologic consequences of a ventricular septal defect are determined by the size of the defect and the relative resistance in the systemic and pul-

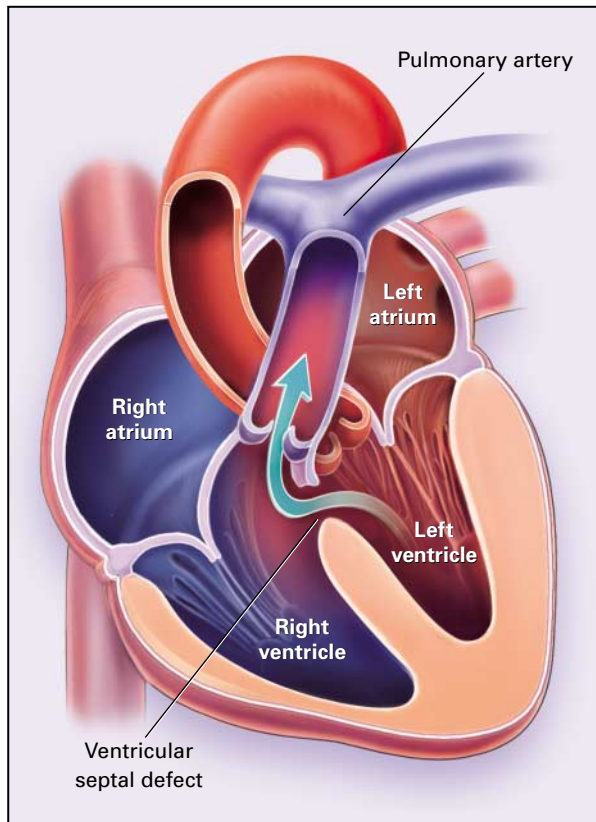


Figure 2. Ventricular Septal Defect with Resultant Left-to-Right Shunting.

When the left ventricle contracts, it ejects some blood into the aorta and some across the ventricular septal defect into the right ventricle and pulmonary artery (arrow).

monary vascular beds. If the defect is small, there is little or no functional disturbance, since pulmonary blood flow is increased only minimally. In contrast, if the defect is large, the ventricular systolic pressures are equal and the magnitude of flow to the pulmonary and systemic circulations is determined by the resistances in the two beds. Initially, systemic vascular resistance exceeds pulmonary vascular resistance, so that left-to-right shunting predominates (Fig. 2). Over time, the pulmonary vascular resistance usually increases, and the magnitude of left-to-right shunting declines. Eventually, the pulmonary vascular resistance equals or exceeds the systemic resistance; the shunting of blood from left to right then ceases, and right-to-left shunting begins.

With substantial left-to-right shunting and little or no pulmonary hypertension, the left ventricular impulse is dynamic and laterally displaced, and the right ventricular impulse is weak. The murmur of a moderate or large defect is holosystolic, loudest at the lower left sternal border, and usually accompanied by a palpable thrill. A short mid-diastolic apical rumble

(caused by increased flow through the mitral valve) may be heard, and a decrescendo diastolic murmur of aortic regurgitation may be present if the ventricular septal defect undermines the valve annulus. Small, muscular ventricular septal defects may produce high-frequency systolic ejection murmurs that terminate before the end of systole (when the defect is occluded by contracting heart muscle). If pulmonary hypertension develops, a right ventricular heave and a pulsation over the pulmonary trunk may be palpated. The holosystolic murmur and thrill diminish and eventually disappear as flow through the defect decreases, and a murmur of pulmonary regurgitation (Graham Steell's murmur) may appear. Finally, cyanosis and clubbing are present.

Electrocardiography and chest radiography provide insight into the magnitude of the hemodynamic impairment. With a small ventricular septal defect, both are normal. With a large defect, there is electrocardiographic evidence of left atrial and ventricular enlargement, and left ventricular enlargement and "shunt vascularity" are evident on the radiograph. If pulmonary hypertension occurs, the QRS axis shifts to the right, and right atrial and ventricular enlargement are noted on the electrocardiogram. The chest film of a patient with pulmonary hypertension shows marked enlargement of the proximal pulmonary arteries, rapid tapering of the peripheral pulmonary arteries, and oligemic lung fields. Two-dimensional echocardiography with Doppler flow can confirm the presence and location of the ventricular septal defect, and color-flow mapping provides information about the magnitude and direction of shunting.^{27,28} With catheterization and angiography, one can confirm the presence and location of the defect, as well as determine the magnitude of shunting and the pulmonary vascular resistance.²⁹

The natural history of ventricular septal defect depends on the size of the defect and the pulmonary vascular resistance. Adults with small defects and normal pulmonary arterial pressure are generally asymptomatic, and pulmonary vascular disease is unlikely to develop.³⁰ Such patients do not require surgical closure, but they are at risk for infective endocarditis^{31,32} and should therefore receive antibiotic prophylaxis. In contrast, patients with large defects who survive to adulthood usually have left ventricular failure or pulmonary hypertension with associated right ventricular failure.¹¹ Surgical closure of the defect is recommended, if the magnitude of pulmonary vascular obstructive disease is not prohibitive. Once the ratio of pulmonary to systemic vascular resistance exceeds 0.7, the risk associated with surgery is prohibitive.

Patent Ductus Arteriosus

The ductus arteriosus connects the descending aorta (just distal to the left subclavian artery) to the left pulmonary artery. In the fetus, it permits pulmonary

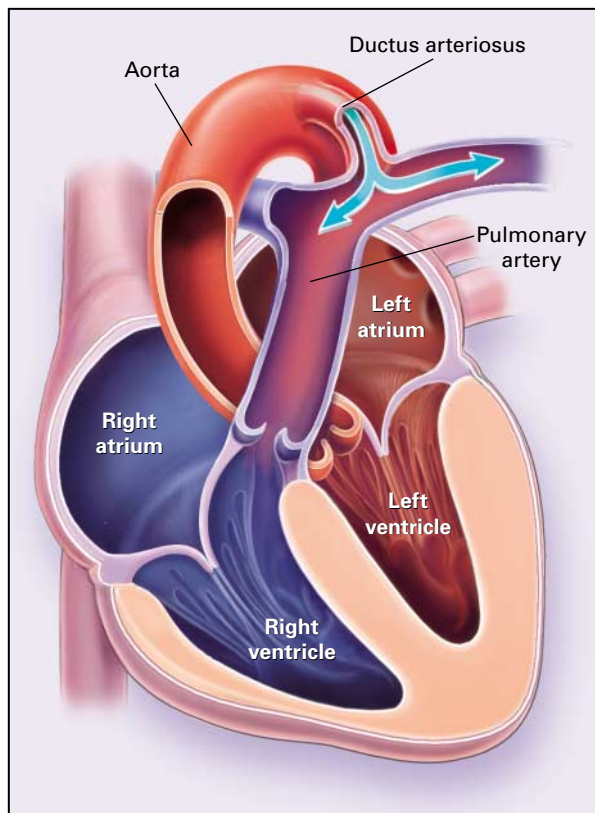


Figure 3. Patent Ductus Arteriosus with Resultant Left-to-Right Shunting.

Some of the blood from the aorta crosses the ductus arteriosus and flows into the pulmonary artery (arrows).

arterial blood to bypass the unexpanded lungs and enter the descending aorta for oxygenation in the placenta. It normally closes soon after birth, but in some infants it does not close spontaneously, and there is continuous flow from the aorta to the pulmonary artery (i.e., left-to-right shunting) (Fig. 3). Patent ductus arteriosus accounts for about 10 percent of cases of congenital heart disease. Its incidence is higher than average in pregnancies complicated by persistent perinatal hypoxemia or maternal rubella infection and among infants born at high altitude or prematurely.

A patient with patent ductus arteriosus and a moderate or large shunt has bounding peripheral arterial pulses, a widened pulse pressure, and a hyperdynamic left ventricular impulse. The first heart sound is normal. A continuous "machinery" murmur, audible in the second left anterior intercostal space, begins shortly after the first heart sound, peaks in intensity at or immediately after the second heart sound (thereby obscuring it), and declines in intensity during diastole. With a large shunt, mid-diastolic and systolic murmurs (from increased flow through the mitral

and aortic valves, respectively) may be noted. If pulmonary vascular obstruction and hypertension develop, the continuous murmur decreases in duration and intensity and eventually disappears and a pulmonary ejection click and a diastolic decrescendo murmur of pulmonary regurgitation may appear.

With a small patent ductus arteriosus, the electrocardiogram and chest x-ray film are normal. With a large patent ductus arteriosus and substantial left-to-right shunting, left atrial and ventricular hypertrophy are evident, and the chest film shows pulmonary plethora, proximal pulmonary arterial dilatation, and a prominent ascending aorta. The ductus arteriosus may be visualized as an opacity at the confluence of the descending aorta and the aortic knob. If pulmonary hypertension develops, right ventricular hypertrophy is noted. With two-dimensional echocardiography, the ductus arteriosus can usually be visualized, and Doppler studies demonstrate continuous flow in the pulmonary trunk.³³ Catheterization and angiography make it possible to quantify the magnitude of shunting and the pulmonary vascular resistance as well as visualize the ductus arteriosus.²⁹

A patent ductus arteriosus rarely closes spontaneously after infancy.³⁴ A small patent ductus arteriosus causes no symptoms, and a person with a defect of this size can have a normal life expectancy. However, the presence of a small patent ductus arteriosus entails an elevated risk of infective endocarditis, which involves the pulmonary side of the ductus arteriosus or the pulmonary artery opposite the duct orifice, from which septic pulmonary emboli may arise. A patent ductus arteriosus of moderate size may cause no symptoms during infancy; during childhood or adulthood, fatigue, dyspnea, or palpitations may appear.^{35,36} In addition, the ductus arteriosus may become aneurysmal and calcified, which may lead to its rupture.³⁷⁻⁴⁰ With larger shunts, flow is markedly increased, which may precipitate left ventricular failure. Eventually, pulmonary vascular obstruction may develop; when the pulmonary vascular resistance equals or exceeds the systemic vascular resistance, the direction of shunting reverses.^{35,41} One third of patients with a patent ductus arteriosus that is not surgically repaired die of heart failure, pulmonary hypertension, or endarteritis by the age of 40 years, and two thirds die by the age of 60 years.^{11,36}

Surgical ligation of patent ductus arteriosus, generally accomplished without cardiopulmonary bypass, has an associated mortality of less than 0.5 percent. However, in patients with ductal aneurysmal dilatation or calcification, resection with cardiopulmonary bypass may be required.^{40,42} Because of the risk of endarteritis associated with unrepaired patent ductus arteriosus (estimated at 0.45 percent annually after the second decade of life)³⁶ and the low risk associated with ligation, we recommend that even a small patent ductus arteriosus be ligated surgically or oc-

cluded with a percutaneously placed closure device. Once severe pulmonary vascular obstructive disease develops, surgical ligation or percutaneous closure is contraindicated.^{40,43}

Aortic Stenosis

The most common pathological finding in patients with symptomatic aortic stenosis who are younger than 65 years of age is a bicuspid aortic valve, which is found in 2 to 3 percent of the population.⁴⁴ It is four times as common in men and boys as in women and girls. Twenty percent of patients with bicuspid aortic valve have an associated cardiovascular abnormality,⁴⁵ such as patent ductus arteriosus or aortic coarctation. In patients with bicuspid aortic valve, the bicuspid valve has a single fused commissure and an eccentrically oriented orifice. Although the deformed valve is not stenotic at birth, it is subjected to abnormal hemodynamic stress, which may lead to thickening and calcification of the leaflets, with resultant immobility. In many patients, there is a coexisting abnormality of the medial layer of the aorta above the valve, which predisposes patients to have dilatation of the aortic root. The area of the aortic orifice in a normal adult is 3.0 to 4.0 cm². Aortic stenosis does not become hemodynamically important unless the valve area is reduced to approximately 1.0 cm².

In patients with severe aortic stenosis, the carotid upstroke is usually delayed and diminished, but it may be normal in elderly patients with noncompliant carotid arteries. The aortic component of the second heart sound is diminished or inaudible, and a fourth heart sound is present. A harsh systolic crescendo-decrescendo murmur is audible over the aortic area and often radiates to the neck. As the aortic stenosis worsens, the murmur peaks progressively later in systole.

Left ventricular hypertrophy results from gradually worsening aortic stenosis and is usually evident on electrocardiography. Unless the left ventricle dilates, the chest x-ray film demonstrates a normal cardiothoracic silhouette. In most patients, transthoracic echocardiography with Doppler flow permits an accurate assessment of the severity of the stenosis and of left ventricular systolic function. Cardiac catheterization is performed to determine the severity of aortic stenosis in cases in which it cannot be assessed noninvasively and to determine whether concomitant coronary artery disease is present.

The classic symptoms of aortic stenosis are angina pectoris, syncope or near-syncope, and heart failure. Adults with aortic stenosis who are asymptomatic have a normal life expectancy; they should receive antibiotic prophylaxis against infective endocarditis. Once symptoms appear, survival is limited: the median survival is only five years after angina develops, three years after syncope occurs, and two years after symptoms of heart failure appear.⁴⁶ Therefore, pa-

tients with symptomatic aortic stenosis should undergo valve replacement.

Pulmonary Stenosis

Pulmonary stenosis constitutes 10 to 12 percent of the cases of congenital heart disease in adults. Obstruction of right ventricular outflow is valvular in 90 percent of patients, and in the remainder it is supralvalvular or subvalvular. Supralvalvular pulmonary stenosis results from the narrowing of the pulmonary trunk, its bifurcation, or its peripheral branches; it often coexists with other congenital cardiac abnormalities (valvular pulmonary stenosis, atrial septal defect, ventricular septal defect, patent ductus arteriosus, or tetralogy of Fallot). It is a common feature of Williams syndrome,⁴⁷ which is characterized by infantile hypercalcemia, elfin facies, and mental retardation, in addition to supralvalvular pulmonary stenosis. Subvalvular pulmonary stenosis, which is caused by the narrowing of the right ventricular infundibulum or subinfundibulum, usually occurs in association with a ventricular septal defect.

Valvular pulmonary stenosis typically is an isolated abnormality, but it may occur in association with ventricular septal defect or lead to secondary hypertrophic subpulmonary stenosis. The valve leaflets usually are thin and pliant; all three valve cusps are present; and the commissures are fused, so that during ventricular systole the valve is dome-shaped with a small central orifice. Among patients with valvular stenosis, 10 to 15 percent have dysplastic leaflets, which are thickened, immobile, and composed of myxomatous tissue. About two thirds of patients with Noonan's syndrome have pulmonary stenosis due to valve dysplasia.⁴⁸

The area of the pulmonary-valve orifice in a normal adult is about 2.0 cm² per square meter of body-surface area, and there is no systolic pressure gradient across the valve. When the valve becomes stenotic, the right ventricular systolic pressure increases and a systolic pressure gradient is observed between the right ventricle and pulmonary artery. Pulmonary stenosis is considered mild if the valve area is larger than 1.0 cm² per square meter, the transvalvular gradient is less than 50 mm Hg, or the peak right ventricular systolic pressure is less than 75 mm Hg. Pulmonary stenosis is considered moderate if the valve area is 0.5 to 1.0 cm² per square meter, the transvalvular gradient is 50 to 80 mm Hg, or the right ventricular systolic pressure is 75 to 100 mm Hg. Severe pulmonary stenosis is characterized by a valve area of less than 0.5 cm² per square meter, a transvalvular gradient of more than 80 mm Hg, or a right ventricular systolic pressure of more than 100 mm Hg.^{49,50}

In patients with moderate or severe pulmonary stenosis, a right ventricular impulse may be palpated at the left sternal border, and there may be a thrill at the second left intercostal space. The first heart sound is normal, and the second heart sound is widely split

but moves normally with respiration; its pulmonary component is soft and delayed. A harsh crescendo-decrescendo systolic murmur that increases in intensity with inspiration is audible along the left sternal border. If the valve is pliable, an ejection click often precedes the murmur; typically, the click softens or disappears with inspiration. As the stenosis becomes more severe, the systolic murmur peaks later in systole and the ejection click moves closer to the first heart sound, eventually becoming virtually superimposed on it.

In cases of moderate or severe pulmonary stenosis, the electrocardiogram shows right-axis deviation and right ventricular hypertrophy. Post-stenotic dilatation of the main pulmonary artery and diminished pulmonary vascular markings are evident on radiography. The cardiac silhouette is usually normal in size. An enlarged cardiac silhouette may be seen if the patient has right ventricular failure or tricuspid regurgitation. On echocardiography, right ventricular hypertrophy and paradoxical septal motion during systole are evident. The site of obstruction can be visualized in most patients. With the use of Doppler flow studies, the severity of stenosis can usually be assessed, so that catheterization and angiography are unnecessary.

The presence or absence of symptoms, their severity, and the prognosis are influenced by the severity of stenosis, the right ventricular systolic function, and the competence of the tricuspid valve.⁵⁰ Adults with valvular pulmonary stenosis are often asymptomatic; in such patients the condition is identified by auscultation of a loud systolic murmur. When the stenosis is severe, dyspnea on exertion or fatigability may occur; less often, patients may have retrosternal chest pain or syncope with exertion. Eventually, right ventricular failure may develop, with resultant peripheral edema and abdominal swelling. Finally, if the foramen ovale is patent, shunting of blood from the right to the left atrium may occur, causing cyanosis and clubbing.

Adults with mild valvular pulmonary stenosis are usually asymptomatic; in such patients the condition does not require correction. Survival among such patients is excellent, with 94 percent still alive 20 years after diagnosis.⁴⁹ Patients with mild valvular stenosis who are undergoing elective dental or surgical procedures should receive antibiotic prophylaxis against infective endocarditis. In contrast, patients with severe stenosis should have the stenosis relieved, since only 40 percent of such patients do not require any intervention by 10 years after diagnosis.⁴⁹ Patients with moderate pulmonary stenosis have an excellent prognosis with either medical or interventional therapy.⁴⁹ Interventional therapy is usually recommended, since most patients with moderate pulmonary stenosis eventually have symptoms requiring such therapy. Relief of valvular stenosis can be accomplished easily and safely with percutaneous balloon valvuloplasty, and a delay

in intervention offers no advantage. Balloon valvuloplasty, the procedure of choice, is usually successful, provided the valve is mobile and pliant; its long-term results are excellent.⁵¹⁻⁵⁵ The secondary hypertrophic subpulmonary stenosis that may occur with valvular stenosis usually regresses after successful intervention.^{52,54} Valve replacement is required if the leaflets are dysplastic or calcified or if marked regurgitation is present.

Aortic Coarctation

Coarctation of the aorta typically consists of a discrete, diaphragm-like ridge extending into the aortic lumen just distal to the left subclavian artery at the site of the aortic ductal attachment (the ligamentum arteriosum) (Fig. 4). This condition results in hypertension in the arms. Less commonly, the coarctation is immediately proximal to the left subclavian artery, in which case a difference in arterial pressure is noted between the arms. Extensive collateral arterial circulation to the distal body through the internal thoracic, intercostal, subclavian, and scapular arteries frequently develops in patients with aortic coarctation. The condition, which is two to five times as fre-

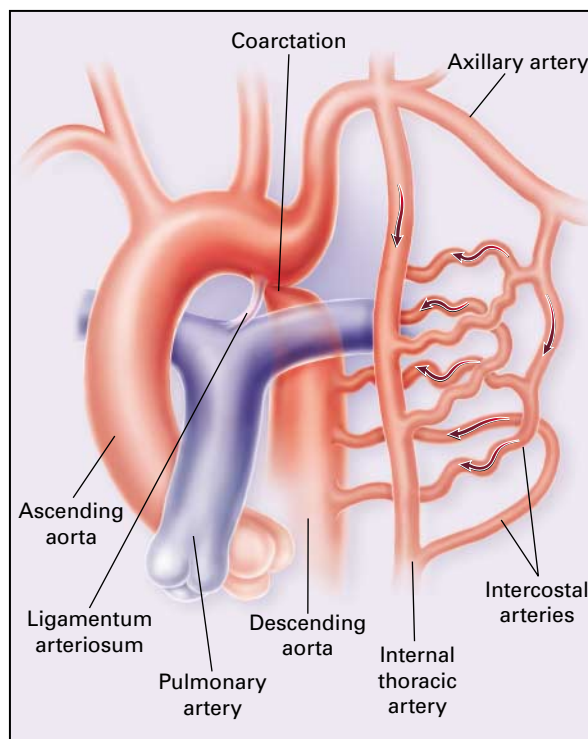


Figure 4. Coarctation of the Aorta.

Coarctation causes severe obstruction of blood flow in the descending thoracic aorta. The descending aorta and its branches are perfused by collateral channels from the axillary and internal thoracic arteries through the intercostal arteries (arrows).

quent in men and boys as in women and girls, may occur in conjunction with gonadal dysgenesis (e.g., Turner's syndrome), bicuspid aortic valve, ventricular septal defect, patent ductus arteriosus, mitral stenosis or regurgitation, or aneurysms of the circle of Willis.^{11,56}

On physical examination, the systolic arterial pressure is higher in the arms than in the legs, but the diastolic pressures are similar; therefore, a widened pulse pressure is present in the arms. The femoral arterial pulses are weak and delayed. A systolic thrill may be palpable in the suprasternal notch, and left ventricular enlargement may be noted. A systolic ejection click (due to a bicuspid aortic valve) is frequently present, and the second heart sound is accentuated. A harsh systolic ejection murmur may be identified along the left sternal border and in the back, particularly over the coarctation. A systolic murmur, caused by flow through collateral vessels, may be heard in the back. In about 30 percent of patients with aortic coarctation, a systolic murmur indicating an associated bicuspid aortic valve is audible at the base.

The electrocardiogram usually shows left ventricular hypertrophy. On the chest radiograph, increased collateral flow through the intercostal arteries causes notching of the posterior third of the third through eighth ribs; such notching is usually symmetric. Notching is not seen in the anterior ribs, since the anterior intercostal arteries are not located in costal grooves. The coarctation may be visible as an indentation of the aorta, and one may see prestenotic and poststenotic dilatation of the aorta, producing the "reversed E" or "3" sign. The coarctation may be visualized echocardiographically, and Doppler examination makes possible an estimate of the transcoarctation pressure gradient. Computed tomography, magnetic resonance imaging, and contrast aortography provide precise anatomical information regarding the location and length of the coarctation; in addition, aortography permits the visualization of the collateral circulation.

Most adults with aortic coarctation are asymptomatic. The diagnosis is made during routine physical examination, when systemic arterial hypertension is observed in the arms, with diminished or absent femoral arterial pulses. When symptoms are present, they are usually those of hypertension: headache, epistaxis, dizziness, and palpitations. Occasionally, diminished blood flow to the legs causes claudication. Patients sometimes seek medical attention because they have symptoms of heart failure or aortic dissection. Women with coarctation are at particularly high risk for aortic dissection during pregnancy.

Complications of aortic coarctation include hypertension, left ventricular failure, aortic dissection, premature coronary artery disease, infective endocarditis, and cerebrovascular accidents (due to the rupture of an intracerebral aneurysm). Two thirds of patients

over the age of 40 years who have uncorrected aortic coarctation have symptoms of heart failure. Three fourths die by the age of 50, and 90 percent by the age of 60.^{11,57}

Surgical repair should be considered for patients with a transcoarctation pressure gradient of more than 30 mm Hg. Although balloon dilatation is a therapeutic alternative, the procedure is associated with a higher incidence of subsequent aortic aneurysm and recurrent coarctation than surgical repair.⁵⁸ Postoperative complications include residual or recurrent hypertension, recurrent coarctation, and the possible sequelae of a bicuspid aortic valve.⁵⁹ The incidence of persistent or recurrent hypertension, as well as the survival rate, is influenced by the patient's age at the time of surgery. Among patients who undergo surgery during childhood, 90 percent are normotensive 5 years later, 50 percent are normotensive 20 years later, and 25 percent are normotensive 25 years later.¹¹ In contrast, among those who undergo surgery after the age of 40 years, half have persistent hypertension, and many of those with a normal resting blood pressure after successful repair have a hypertensive response to exercise.

Similarly, survival after repair of aortic coarctation is also influenced by the age of the patient at the time of surgery. After surgical repair during childhood, 89 percent of patients are alive 15 years later and 83 percent are alive 25 years later. When repair of coarctation is performed when the patient is between the ages of 20 and 40 years, the 25-year survival is 75 percent. When repair is performed in patients more than 40 years old, the 15-year survival is only 50 percent.^{11,60}

REFERENCES

1. Moodie DS. Adult congenital heart disease. *Curr Opin Cardiol* 1994; 9:137-42.
2. Feldt RH, Avasthey P, Yoshimasu F, Kurland LT, Titus JL. Incidence of congenital heart disease in children born to residents of Olmsted County, Minnesota, 1950-1969. *Mayo Clin Proc* 1971;46:794-9.
3. Campbell M. Natural history of atrial septal defect. *Br Heart J* 1970; 32:820-6.
4. Leachman RD, Cokkinos DV, Cooley DA. Association of ostium secundum atrial septal defects with mitral valve prolapse. *Am J Cardiol* 1976;38: 167-9.
5. Van Praagh S, Carrera ME, Sanders SP, Mayer JE, Van Praagh R. Sinus venosus defects: unroofing of the right pulmonary veins — anatomic and echocardiographic findings and surgical treatment. *Am Heart J* 1994;128: 365-79.
6. Holt M, Oram S. Familial heart disease with skeletal malformations. *Br Heart J* 1960;22:236-42.
7. Basson CT, Cowley GS, Solomon SD, et al. The clinical and genetic spectrum of the Holt-Oram syndrome (heart-hand syndrome). *N Engl J Med* 1994;330:885-91. [Erratum, *N Engl J Med* 1994;330:1627.]
8. Lynch HT, Bachenberg K, Harris RE, Becker W. Hereditary atrial septal defect: update of a large kindred. *Am J Dis Child* 1978;132:600-4.
9. Pease WE, Nordenberg A, Ladda RL. Familial atrial septal defect with prolonged atrioventricular conduction. *Circulation* 1976;53:759-62.
10. O'Toole JD, Reddy PS, Curtiss EI, Shaver JA. The mechanism of splitting of the second heart sound in atrial septal defect. *Circulation* 1977;56: 1047-53.
11. Perloff JK. Survival patterns without cardiac surgery or interventional catheterization: a narrowing base. In: Perloff JK, Childs JS, eds. *Congenital heart disease in adults*. 2nd ed. Philadelphia: W.B. Saunders, 1998:15-53.
12. Shub C, Dimopoulos IN, Seward JB, et al. Sensitivity of two-dimen-

- sional echocardiography in the direct visualization of atrial septal defect utilizing the subcostal approach: experience with 154 patients. *J Am Coll Cardiol* 1983;2:127-35.
13. Adams CW. A reappraisal of life expectancy with atrial shunts of the secundum type. *Dis Chest* 1965;48:357-75.
 14. Craig RJ, Selzer A. Natural history and prognosis of atrial septal defect. *Circulation* 1968;37:805-15.
 15. Markman P, Howitt G, Wade EG. Atrial septal defect in the middle-aged and elderly. *QJM* 1965;34:409-26.
 16. Mattila S, Merikallio E, Tala P. ASD in patients over 40 years of age. *Scand J Thorac Cardiovasc Surg* 1979;13:21-4.
 17. Perloff JK. Ostium secundum atrial septal defect — survival for 87 and 94 years. *Am J Cardiol* 1984;53:388-9.
 18. Murphy JG, Gerst BJ, McGoan MD, et al. Long-term outcome after surgical repair of isolated atrial septal defect: follow-up at 27 to 32 years. *N Engl J Med* 1990;323:1645-50.
 19. Konstantinides S, Geibel A, Olschewski M, et al. A comparison of surgical and medical therapy for atrial septal defect in adults. *N Engl J Med* 1995;333:469-73.
 20. Gatzoulis MA, Freeman MA, Siu SC, Webb GD, Harris L. Atrial arrhythmia after surgical closure of atrial septal defects in adults. *N Engl J Med* 1999;340:839-46.
 21. Steele PM, Fuster V, Cohen M, Ritter DG, McGoan DC. Isolated atrial septal defect with pulmonary vascular obstructive disease — long-term follow-up and prediction of outcome after surgical correction. *Circulation* 1987;76:1037-42.
 22. Rickers C, Hamm C, Stern H, et al. Percutaneous closure of secundum atrial septal defect with a new self centering device ("angel wings"). *Heart* 1998;80:517-21.
 23. Lambert V, Losay J, Piot J-D, et al. Complications tardives après fermeture percutanée des communications interauriculaires par prothèse bounnée de Sideris. *Arch Mal Coeur Vaiss* 1997;90:245-51.
 24. Dajani AS, Taubert KA, Wilson W, et al. Prevention of bacterial endocarditis: recommendations by the American Heart Association. *JAMA* 1997;277:1794-801.
 25. Weidman WH, DuShane JW, Ellison RC. Clinical course in adults with ventricular septal defect. *Circulation* 1977;56:Suppl I:1-78-1-79.
 26. Graham TP Jr, Gutgesell HP. Ventricular septal defects. In: Emmanouilides GC, Riemenschneider TA, Allen HD, Gutgesell HP, eds. *Moss and Adams heart disease in infants, children, and adolescents*. Baltimore: Williams & Wilkins, 1995:724-46.
 27. Pieroni DR, Nishimura RA, Bierman FZ, et al. Second natural history study of congenital heart defects: ventricular septal defect: echocardiography. *Circulation* 1993;87:Suppl I:1-80-1-88.
 28. Valdes-Cruz LM, Cayre RO. Ventricular septal defects. In: Valdes-Cruz LM, Cayre RO, eds. *Echocardiographic diagnosis of congenital heart disease: an embryologic and anatomic approach*. Philadelphia: Lippincott-Raven, 1999:199-213.
 29. Boehrer JD, Lange RA, Willard JE, Grayburn PA, Hillis LD. Advantages and limitations of methods to detect, localize, and quantitate intracardiac left-to-right shunting. *Am Heart J* 1992;124:448-55.
 30. Kidd L, Driscoll DJ, Gersony WM, et al. Second natural history study of congenital heart defects: results of treatment of patients with ventricular septal defects. *Circulation* 1993;87:Suppl I:1-38-1-51.
 31. Neumayer U, Stone S, Somerville J. Small ventricular septal defects in adults. *Eur Heart J* 1998;19:1573-82.
 32. Gersony WM, Hayes CJ, Driscoll DJ, et al. Bacterial endocarditis in patients with aortic stenosis, pulmonary stenosis, or ventricular septal defect. *Circulation* 1993;87:Suppl I:1-121-1-126.
 33. Takenaka K, Sakamoto T, Shiota T, Amano W, Igarashi T, Sugimoto T. Diagnosis of patent ductus arteriosus in adults by biplane transesophageal color Doppler flow mapping. *Am J Cardiol* 1991;68:691-3.
 34. Coggin CJ, Parker KR, Keith JD. Natural history of isolated patent ductus arteriosus and the effect of surgical correction: twenty years' experience at the Hospital for Sick Children, Toronto. *CMAJ* 1970;102:718-20.
 35. Campbell M. Patent ductus arteriosus: some notes on prognosis and on pulmonary hypertension. *Br Heart J* 1955;17:511-33.
 36. *Idem*. Natural history of persistent ductus arteriosus. *Br Heart J* 1968;30:4-13.
 37. Ohtsuka S, Kakihana M, Ishikawa T, et al. Aneurysm of patent ductus arteriosus in an adult case: findings of cardiac catheterization, angiography, and pathology. *Clin Cardiol* 1987;10:537-40.
 38. Lund JT, Jensen MB, Hjelms E. Aneurysm of the ductus arteriosus: a review of the literature and the surgical implications. *Eur J Cardiothorac Surg* 1991;5:566-70.
 39. Kelly DT. Patent ductus arteriosus in adults. *Cardiovasc Clin* 1979;10:321-6.
 40. Fisher RG, Moodie DS, Sterba R, Gill CC. Patent ductus arteriosus in adults — long-term follow-up: nonsurgical versus surgical treatment. *J Am Coll Cardiol* 1986;8:280-4.
 41. Espino-Vela J, Cardenas N, Cruz R. Patent ductus arteriosus: with special reference to patients with pulmonary hypertension. *Circulation* 1968;38:Suppl I:1-45-1-60.
 42. Bell-Thomson J, Jewell E, Ellis FH Jr, Schwaber JR. Surgical technique in the management of patent ductus arteriosus in the elderly patient. *Ann Thorac Surg* 1980;30:80-3.
 43. John S, Muralidharan S, Jairaj PS, et al. The adult ductus: review of surgical experience with 131 patients. *J Thorac Cardiovasc Surg* 1981;82:314-9.
 44. Subramanian R, Olson LJ, Edwards WD. Surgical pathology of pure aortic stenosis: a study of 374 cases. *Mayo Clin Proc* 1984;59:683-90.
 45. Friedman WF. Aortic stenosis. In: Emmanouilides GC, Riemenschneider TA, Allen HD, Gutgesell HP, eds. *Moss and Adams heart disease in infants, children, and adolescents*. Baltimore: Williams & Wilkins, 1995:1087-111.
 46. Carabello BA, Crawford FA Jr. Valvular heart disease. *N Engl J Med* 1997;337:32-41. [Erratum, *N Engl J Med* 1997;337:507.]
 47. Zalzstein E, Moes CA, Musewe NN, Freedom RM. Spectrum of cardiovascular anomalies in Williams-Beuren syndrome. *Pediatr Cardiol* 1991;12:219-23.
 48. Pearl W. Cardiovascular anomalies in Noonan's syndrome. *Chest* 1977;71:677-9.
 49. Hayes CJ, Gersony WM, Driscoll DJ, et al. Second natural history study of congenital heart defects: results of treatment of patients with pulmonary valvar stenosis. *Circulation* 1993;87:Suppl I:1-28-1-37.
 50. Kaplan S, Perloff JK. Exercise and athletics before and after cardiac surgery or interventional catheterization. In: Perloff JK, Childs JC, eds. *Congenital heart disease in adults*. 2nd ed. Philadelphia: W.B. Saunders, 1998:189-98.
 51. Sadr-Ameli MA, Sheikholeslami F, Firoozi I, Azarnik H. Late results of balloon pulmonary valvuloplasty in adults. *Am J Cardiol* 1998;82:398-400.
 52. Teupe CH, Burger W, Schrader R, Zeiher AM. Late (five to nine years) follow-up after balloon dilation of valvular pulmonary stenosis in adults. *Am J Cardiol* 1997;80:240-2.
 53. Chen C-R, Cheng TO, Huang T, et al. Percutaneous balloon valvuloplasty for pulmonic stenosis in adolescents and adults. *N Engl J Med* 1996;335:21-5.
 54. Fawzy ME, Galal O, Dunn B, Shaikh A, Sriram R, Duran CM. Regression of infundibular pulmonary stenosis after successful balloon pulmonary valvuloplasty in adults. *Cathet Cardiovasc Diagn* 1990;21:77-81.
 55. Kaul UA, Singh B, Tyagi S, Bhargava M, Arora R, Khalilullah M. Long-term results after balloon pulmonary valvuloplasty in adults. *Am Heart J* 1993;126:1152-5.
 56. Mazzanti L, Prandstraller D, Tassinari D, et al. Heart disease in Turner's syndrome. *Helv Paediatr Acta* 1988;43:25-31.
 57. Campbell M. Natural history of coarctation of the aorta. *Br Heart J* 1970;32:633-40.
 58. Shaddy RE, Boucek MM, Sturtevant JE, et al. Comparison of angioplasty and surgery for unoperated coarctation of the aorta. *Circulation* 1993;87:793-9.
 59. Cohen M, Fuster V, Steele PM, Driscoll D, McGoan DC. Coarctation of the aorta: long-term follow-up and prediction of outcome after surgical correction. *Circulation* 1989;80:840-5.
 60. Coarctation of the aorta and interrupted aortic arch. In: Kirkin JW, Barratt-Boyes BG. *Cardiac surgery: morphology, diagnostic criteria, natural history, techniques, results, and indications*. 2nd ed. Vol. 2. New York: Churchill Livingstone, 1993:1263-325.