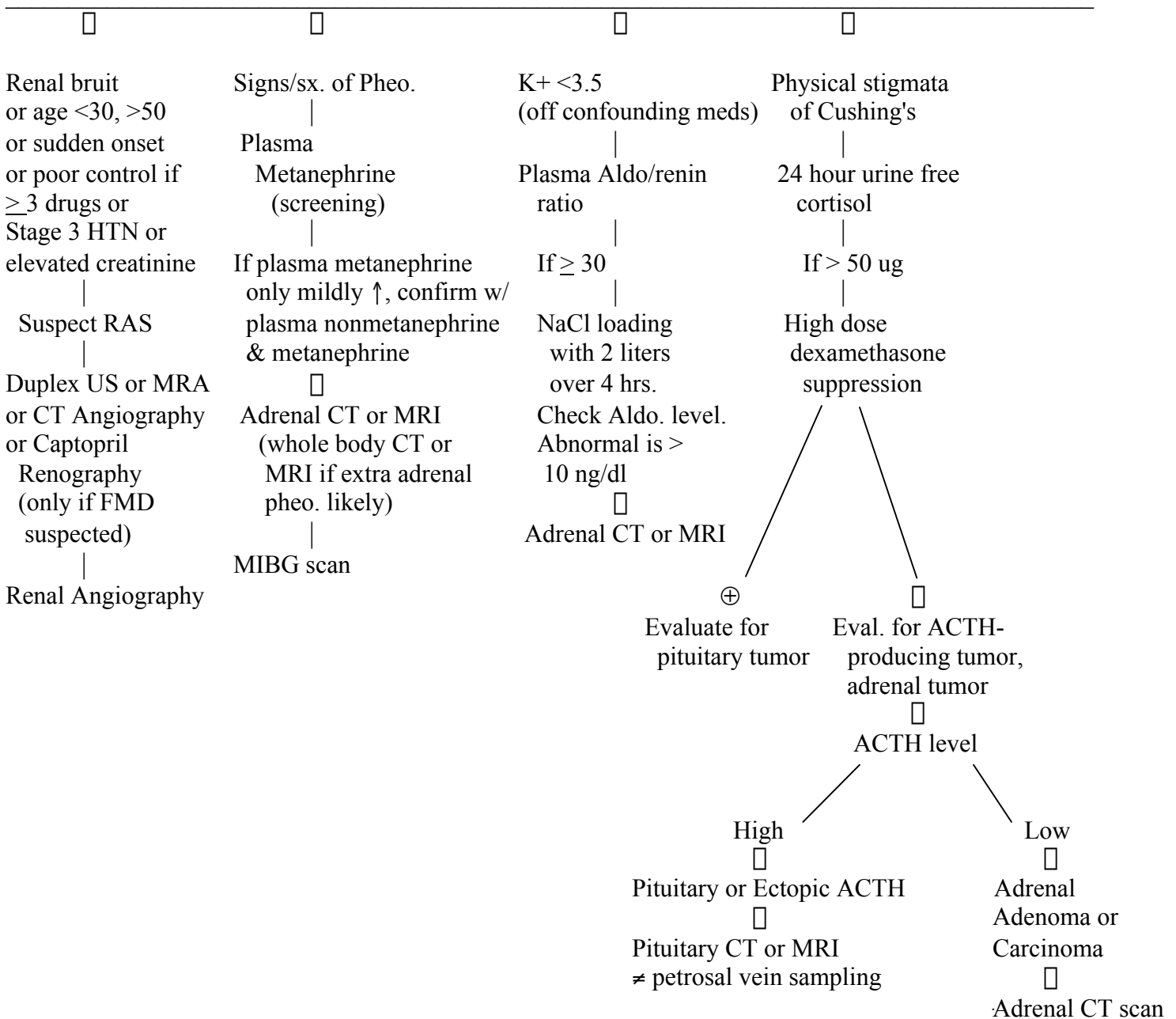


**SECONDARY HYPERTENSION
MEDPLEX CONFERENCE
J. LEWIS, M.D.
MARCH 2002**

HTN Suspicious of 2° Cause (CRI, Coarct, RAS, Cushing's, HPT,
Thyrotosis, 1° Aldo, Pheo, OSA, EtOH, OCPs, other Cocaine Meds)

□
UA, CBC, BMP, FLP, EKG

□
Suspicious for 2° cause: Age <30 or >50. HTN despite 3-drug rx., Stage 3 HTN (≥ 180/110), sudden
↑ in well-controlled HTN, HA/palpitation/pallor/sweats, renal bruit, SBP in legs ≤ 20 mm SBP in arms,
Cushing's physical stigmata, K+ <3.5, elevated creatinine, elevated calcium, abnormal UA.



**SECONDARY HYPERTENSION
MEDPLEX CONFERENCE
J. LEWIS, M.D.
MARCH 2002**

Intro: Please review flow chart and then answer questions. Caveat: there is debate over choice and interpretation of screening tests. For teaching purposes, the debates are omitted.

QUESTIONS:

1. Identify the one clinical finding that does not mandate looking for a secondary cause of HTN.
 - a. 24 y.o. woman with moderate-severe HTN.
 - b. K+ < 3.5 without treatment.
 - c. SBP differential of > 20 mm Hg between arms and legs.
 - d. Truncal obesity and purple striae.
 - e. Epigastric bruit in a 60 y.o. with BP of 165/102.
 - f. Failure to control HTN despite three medications at maximal doses.
 - g. Abrupt increase in BP in a previously well-controlled hypertensive.
 - h. Tachycardia, sweating, and severe headaches without apparent cause.

2. True or False
 - a. A patient with a cerebellar hemangioblastoma should be screened for pheochromocytoma.
 - b. Renovascular hypertension should be considered in a patient who presents with accelerated or malignant HTN.
 - c. Appropriate initial drug treatment for a patient with a pheo. is a β -blocker followed by an alpha blocker if needed.
 - d. An acute decline in renal function after treatment with an ACE inhibitor is suggestive of RAS.
 - e. Hypertension secondary to oral contraceptive use will usually resolve within one month after stopping the drug.

3. A 73 y.o. man has hypertension increasingly difficult to control over the last six months. His medications are HCTZ - 25 mg/d, Lisinopril - 40 mg/d, and Nifedipine SR - 120 mg/d. His current BP is 178/112. He has bilateral flank bruits, and his creatinine has increased from 1.2 to 1.9. A renal angiogram (indicated initially in a high probability situation) shows hemodynamically significant atherosclerotic proximal RAS. Which of the following statements is true?
 - a. His HTN is more likely to be helped by percutaneous transluminal renal angioplasty than in a patient with fibromuscular dysplasia.
 - b. This patient may be satisfactorily treated by adding an AII RB.
 - c. Asymmetric renal size noted on an US or CT performed for other reasons may be an early indication of RAS.

References:

1. Harrison's Textbook of Medicine, 2001.
2. Saran & Textor. Renal artery stenosis. NEJM 2001;344:431-442.
3. Pacak et al. Recent advances in genetics, diagnosis, localization, and treatment of pheochromocytoma. Ann Intern Med 2001;134:315-329.
4. Up-to-Date. 2002.